
An Investigation into the Functions of the Occipital and Temporal Lobes of the Monkey's Brain

Sanger Brown and E. A. Schafer

Phil. Trans. R. Soc. Lond. B 1888 **179**, 303-327
doi: 10.1098/rstb.1888.0011

References

Article cited in:

<http://rstb.royalsocietypublishing.org/content/179/303.citation#related-urls>

Email alerting service

Receive free email alerts when new articles cite this article - sign up in the box at the top right-hand corner of the article or click [here](#)

To subscribe to *Phil. Trans. R. Soc. Lond. B* go to: <http://rstb.royalsocietypublishing.org/subscriptions>

XI. *An Investigation into the Functions of the Occipital and Temporal Lobes of the Monkey's Brain.*

By SANGER BROWN, M.D., and E. A. SCHÄFER, F.R.S., *Jodrell Professor of Physiology in University College, London.**

Received November 24,—Read December 15, 1887.

[PLATES 48–50.]

THE experiments which we here record were performed during the preceding winter and spring in the physiological laboratory of University College, but their formal publication has been hitherto deferred because we were desirous of keeping some of the animals in which the lesions had been established under observation during several months, in order that any modification which that lapse of time might produce in the symptoms should be duly recorded. But, although not hitherto published, several of the cases, while still under such observation, have been brought before the notice of both the Physiological and the Neurological Society of London, and have been examined at different times by various persons interested in the subject of cerebral localisation, besides being familiar to the regular workers in the laboratory. In this way we have repeatedly had the opportunity of showing most of the symptoms which we are about to record, nor have we inserted any detail as to the accuracy of which there could, to an unbiased mind, be the slightest doubt.

All our experiments have been performed with the view of establishing certain lesions, uni- or bi-lateral, embracing definite areas of the cerebral cortex; and they have been confined, or nearly so, to the occipital and temporal lobes. In the performance of the operations strict antiseptic precautions were employed, the dressings being fixed by a collodion cap. On the fourth or fifth day after the operation this cap

* I desire to acknowledge the assistance I have received, both from the Association for the Advancement of Medicine by Research and from the Government Grant Fund of the Royal Society, in aid of this series of researches. By a grant obtained from the Association many of the expenses attendant upon the procuring and keep of the animals have been met, while the Government grant has enabled me to secure the services of an able assistant (Mr. E. P. FRANCE), who has devoted a large part of his time to a careful *post-mortem* investigation of each case, with a view to the precise determination of the extent of the lesion, together with consequent degenerative changes in other parts of the central nervous system. The latter part of Mr. FRANCE'S work must necessarily still occupy a considerable time, and any results which it may yield will be the subject of a future communication.—E. A. S.

15.8.88

and the dressings were removed, and in every case the wound was found to be completely closed, the edges of the skin being closely united, no sign of meningitis nor of any septic mischief being at any time perceptible. In one exceptional case, however, in which the antiseptic precautions had, from over confidence, been relaxed, the asepticism was incomplete, and sloughing of the skin over the seat of operation resulted, so that the animal had to be killed within a few days of the performance of the operation. This case will be mentioned in due course.

In a few instances, after exposing the part of the brain which was to be removed, and previous to such removal, we explored the exposed surface with the interrupted current. Since in these cases the surface of the brain had been exposed to the influence of carbolic acid, and, moreover, the animal was somewhat deeply anæsthetized, the results were somewhat uncertain, and in very many cases negative, even from parts where the experiments of previous observers would have led one to expect positive results. These incidental electrical explorations are not, therefore, of very great value, especially where their result has been negative; but such positive results as we succeeded in obtaining were duly recorded, so as to be available for future use. They will not, however, be included in the present communication.

We will now pass to the actual record of our experiments, giving them in the order in which they were performed. Afterwards we shall endeavour to point out the conclusions which seem to us to be warranted by the results which we have obtained, and to show in what particulars they agree with or differ from the results obtained by other experimenters.

I.

A small but vigorous Jew Monkey, ♂.

First Operation.—Removal of the anterior extremity (apex) of the right temporal lobe. [The *post-mortem* examination of the brain showed that the entire mesial aspect of the apex was not included in the lesion.]

Result.—Attempts were made to determine whether sapid substances were less readily detected upon one side of the mouth than the other, but without success.

Second Operation.—This was performed a week after the first, the same lesion being established upon the other side of the brain.

Result.—Two days after this second operation, the animal, which was quite normal in its behaviour and appearance, and showed no signs of any motor paralysis nor any deficiency in sight, hearing, or general sensation, was tested in the following way:—Raisins and pieces of apple were given, and devoured with gusto. A raisin was then stuffed with sulphate of quinine, so that the drug was entirely concealed; this was seized and bitten eagerly as usual. But as soon as the quinine was reached the animal showed signs of dissatisfaction, smelled the raisin several times, appeared to taste it again, and finally threw it away. A piece of apple was then taken and its surface covered with the drug, which was rubbed in so as not to be recognisable by

the eye. After smelling the piece suspiciously, the Monkey bit off a portion with apparent confidence, but promptly rejected it. The same operation of smelling and tasting was repeated two or three times, and then the piece of apple was definitively thrown away.

This experiment was frequently repeated with a like result, although sometimes, when the animal was hungry, the food would be eaten in spite of the quinine. When, however, instead of sulphate of quinine the more soluble hydrochlorate of the alkaloid was given (especially when a little liquor strychniæ had been added) concealed in the food, the grimacing and other signs of disgust were very marked, and persisted for a considerable time.

Third Operation.—The third operation was performed five weeks after the second one, and consisted in the destruction by the actual cautery of the grey matter of the superior temporal convolution of each hemisphere.

The day after this operation the animal is lively and well, and appears to hear as well as ever, so far as one can judge by his reaction to sounds. The other senses appear also to be unaffected.

On subsequent days the Monkey was repeatedly tested as to taste, sight, hearing, smell, and general sensibility, without any defect being noticeable.

A few days after the operation a patch of dry gangrene appeared on the front of the right leg, which was followed by sloughing of the skin and exposure of the muscles of the part. As the affection showed some tendency to spread, it was judged advisable to kill the animal, and this was accordingly done, by chloroform, on the fourteenth day after the third operation.

Autopsy: Condition of the Brain.—*On the right side* (Plate 48, fig. 1*a*) there is a little softening apparent along the edge of the operculum, extending as far as the level of the lower end of the interparietal furrow, and the dura mater is somewhat adherent over this patch. The upper margin of the middle temporal gyrus is considerably damaged. The superior temporal gyrus is completely destroyed. The outer half of the anterior extremity of the temporal lobe is removed, but the inner half remains (fig. 1*b*).

On the left side (Plate 48, fig. 1*c*) there is slight adhesion of the dura on either side of the lower end of the fissure of ROLANDO. A narrow line of softening along the upper border of the middle temporal gyrus. The superior temporal gyrus is entirely destroyed, with the exception of its uppermost extremity, about 8 or 9 millims. ($\frac{1}{3}$ -inch) of which is left.

The brain is shown in Plate 48, figs. 1*a* (right hemisphere), 1*b* (left hemisphere), and 1*c* (from below).

Remarks.—The results obtained in this animal appear to show that very considerable lesions of the anterior extremity of the temporal lobe may exist in a Monkey without any appreciable impairment either of smell or taste, and that the superior temporal gyrus may be completely destroyed on one side and almost completely on the other without any appreciable impairment of hearing.

II.

Rhesus Monkey. When received, the animal was very wild and fierce, but was carefully tamed until he would readily take food from the hand. His senses, especially that of taste, were thoroughly tested. He invariably declined to eat food which was rendered bitter by quinine, expressing a lively disgust by grimacing and endeavouring to remove the impression from the mouth by his fingers.

First Operation.—The operation was bilateral, the anterior extremity of each temporal lobe being removed. This was done by vertical incision, and the *post mortem* examination showed the removal to be virtually complete.

Result.—The animal was first tested for taste on the second day, and gave no signs of any impairment of that sense. Subsequently the test was frequently repeated, always with the same result. Nor could any defect in any other of the special senses be appreciated. There was no motor paralysis.

Second Operation.—Three weeks after the first operation, the Monkey remaining perfectly well, a second lesion was established on the right side, the *occipital lobe* of that side being completely removed.

The day after the animal is quite well and lively, but is hemiopic. Careful and repeated tests (offers of food, threats, &c.), show distinctly that there is no visual appreciation of objects on the left of the mesial plane. Objects brought across the visual field of either eye (the other being bandaged) from the left are not noticed until they reach the mesial plane.

On the morning of the fifth day it was found that the animal had managed to remove the dressing and open the wound. It was therefore judged advisable, since the wound was no longer aseptic and would probably become inflamed, to kill the animal. This was accordingly done, and the brain examined.

Autopsy: Condition of Brain.—The tips of the temporal lobes are entirely removed to a longitudinal extent of about half an inch on both sides. Beyond this there is no sign of inflammation or softening. The right occipital lobe is removed except a small part of the external surface. The rest of the brain appears perfectly healthy. The angular gyrus is intact,

The brain is shown in Plate 48, figs. 2*a* and 2*b*.

Remarks.—As regards the tips of the temporal lobes, this is a more satisfactory experiment than the preceding, inasmuch as the removal is very complete, and taste and smell, nevertheless, seem in no way impaired. The result of the occipital lesion is of value merely as an *immediate* result of such an operation: it does not settle the question whether removal of this part is followed by permanent blindness, but it shows conclusively that hemiopia may be produced without any inclusion of the angular gyrus.

III.

The variety of Monkey is not recorded in the notes ; ♂ ; very tame.

First Operation.—Destruction of the left superior temporal convolution by the galvanic cautery. No permanent symptoms resulted from this operation.

Second Operation.—Four months subsequently the whole of the right temporal lobe was removed by the knife.

Result.—Tested the day after the operation, all the senses were somewhat deadened. On the second day, however, they have completely recovered. Hearing is quite acute, even a slight rustle, such as that caused by crushing a piece of paper in the hands, immediately attracting the animal's attention. Plugging the right ear with cotton wool did not appreciably affect the result.

This Monkey continued to enjoy excellent health and to exhibit the complete possession of all his senses during a fortnight, at the end of which time a *Third Operation*—viz., the removal of the remainder of the left temporal lobe—was attempted ; but unsuccessfully, for the animal did not recover from the shock of the operation.

Autopsy.—On the right side the whole temporal lobe was found to have been removed or destroyed.

On the left side the removal of the lobe is also nearly complete. The superior gyrus is destroyed, and the injury even extends across the Sylvian fissure to the lower anterior end of the angular gyrus. More anteriorly, however, there is a narrow strip of the superior gyrus, about 2 millims. wide, left along the Sylvian fissure. This only includes grey matter ; its white centre is completely gone.

The brain is shown in Plate 48, figs. 3*a*, 3*b*, and 3*c*, and in section in figs. 3*d*, 3*e*, and 3*f*. The sections are vertical, and pass through the anterior, the middle, and the posterior parts of the lesion respectively.

Remarks.—When the left side was exposed for the third operation it was found that the destruction of the superior temporal gyrus was practically complete, if we except the small strip just mentioned, which itself showed signs of having been injured by the cautery. This experiment is therefore one in which both superior temporal gyri were extensively, almost entirely, destroyed ; indeed, it is scarcely possible to suppose that the very small strip which was left could carry on the function of both convolutions without any perceptible diminution. It must therefore be held to tell strongly against the entire localisation of auditory perceptions in this gyrus. The remainder of the right temporal lobe was also removed ; but, as the bilateral establishment of the complete lesion was unsuccessful, no deductions can be drawn from the absence of positive symptoms following the unilateral lesion, and the experiment is of value only as a bilateral lesion of the superior gyri.

IV.

Rhæsus Monkey ; a fine specimen. Was frequently tested prior to operation.

The *Operation* consisted in the complete removal of the whole of the right temporal lobe, down to the edge of the crus cœrebrî, and including the hippocampus major. Behind, the lesion extended partly over the under surface of the occipital lobe.

Result.—Two days after the operation the following notes were taken :—There is distinct facial paralysis (left side). There is also right hemianopsia. Reactions to tactile impressions applied to the left side of the body are much diminished. When pricked with a needle upon the left side, scratches the spot pricked, but does not show evidence of feeling pain from the prick. On the right side, on the other hand, there is prompt reaction both to tactile and painful impressions.

On the eighth day the reaction to touch and to pricking is nearly, if not quite, equal on the two sides, but the facial paralysis and hemiopia persist.

On the seventeenth day the animal had to be killed, because the skin wound had become re-opened, and there was evidence of the commencement of inflammation and hernia cerebri.

Autopsy.—The right temporo-sphenoidal lobe was found to be completely destroyed ; the commencing hernia had produced a slight prominence of the brain over the seat of lesion. The upper part of the right occipital lobe is slightly yellowish, as if from commencing softening.

The brain is represented in Plate 49, fig. 4*a*, from the side, and in fig. 4*b* from below.

Remarks.—The lesion not being bilateral, experiments upon hearing, smell, and taste could not be satisfactorily carried out. The hemiopia was probably due to a large portion of the occipital lobe having accidentally become involved, at least in its vascular supply ; the facial paralysis to obliteration of vessels proceeding to the "facial area" from the Sylvian fissure. The affection of general and tactile sensibility may be due to the fact that the hippocampal region was involved in the removal.

This case furnishes an illustration of the fact that hernia cerebri is apt to accompany the establishment of a septic condition in the exposed brain.

V.

A small but vigorous and intelligent *Rhæsus* Monkey, ♀.

First Operation.—The left angular gyrus was destroyed by actual cautery.

The result of this operation was absolutely *nil*, so far as we were able to determine. Even an hour or two after the establishment of the lesion and recovery from the effects of the anæsthetic, no impairment of vision could be detected. On bandaging the left eye the animal still saw perfectly well with the other one, took food from the hand, avoided obstacles, and generally displayed every token of the possession of clear

visual perceptions. There was no loss of movement of the eyeball or eyelid, nor any anæsthesia of the cornea.

Second Operation.—Was performed eight days after the first, and consisted in the destruction of the remaining angular gyrus in the same manner.

Tested in less than an hour after the operation, shows no impairment of vision, nor of the motion of the eyeballs or lids, nor was the cornea of either eye rendered anæsthetic, or even, so far as could be determined, diminished in sensibility. The animal was kept for a month without further operation, during which time it was frequently tested, but always with negative results.

Third Operation.—A month after the last. This operation was intended to effect the destruction of the superior temporal gyri on both sides, the greater part being cut away with the knife, and the destruction of the remainder right up to the bounding fissures being completed by the actual cautery. It was found, however, on *post-mortem* examination, that on the right side the second temporal gyrus had been mistaken for the first, and that the latter had remained almost intact. This mistake was not suspected during life, and the animal was always shown as one with both superior temporal gyri destroyed.

Results.—The only noticeable symptom in this animal is an apparent stiffness of the neck, so that when she desires to rotate the head, the shoulders and upper part of the trunk move also. This appears to produce a certain amount of reluctance to turn towards sounds and objects which might attract the attention, and a consequent appearance of stupidity; but she nevertheless gives unmistakable signs that she hears acutely, and also that she is able to localise the direction of sounds. No other symptoms but the one mentioned—the appearance, namely, of stiffness of the neck—could be detected in this animal, although she was under daily observation for some months, and was frequently carefully tested with respect to all the special senses.

About four months after the first operation, having been in very fair health during that time, the animal was seized with epileptiform convulsions, which continued without intermission for a number of hours and only ended with death.

Autopsy: Condition of the Brain.—The superficial grey matter of both angular gyri is destroyed. The lesion also involves the posterior border of the external parieto-occipital fissure. On the left side the superior temporal gyrus is destroyed. On the right side this convolution remains, but the second temporal gyrus and the portion of the temporal lobe immediately below it are destroyed. The rest of the brain is healthy, with the exception of a small patch of yellow softening in the middle of the left ascending parietal gyrus.

The brain is represented in Plate 49, figs. 5*a*, 5*b*, and 5*c*.

Remarks.—This experiment is of especial interest, firstly on account of the totally negative results, both immediate and remote, of decortication of the angular gyri; secondly, by reason of the peculiar stiffness and immobility of the neck which followed the second operation; and thirdly, because it is the only one of our experi-

ments upon the upper part of the temporal lobe as to the result of which any decided doubt was expressed by outside observers to whom the animals were from time to time exhibited. The doubt expressed was as to the possession of the auditory faculties, and probably arose from the peculiar stiffness and reluctance to turn the head which has been recorded. We ourselves, and all who have had much to do with the Monkeys, obtained on so many occasions abundant evidence of acuteness of hearing that we never shared the doubt in the slightest degree, although we performed the operation in the hope and expectation that hearing would be decidedly affected or totally destroyed. For our previous experiments had shown that both superior temporal gyri could be destroyed without loss of hearing; we thought it possible, however, that if this lesion were combined with the destruction of the angular gyri a positive result might be obtained. In other words, we were desirous of testing the question whether the centre for auditory impressions were localised in these two gyri (the angular and superior temporal), which are anatomically almost continuous with one another, and which we thought might also have a physiological connexion. But our expectations were disappointed, as we had no difficulty in observing, and as we also had no difficulty in convincing most other observers. Of course, it must be borne in mind, what we were at the time of testing in ignorance of, that the lesion was not that which we supposed it to be, since only one of the superior temporal gyri was involved in it.

VI.

A fine, large, active *Rhæsus* Monkey, ♂.

First Operation.—Complete removal of the right temporal lobe.

Result.—Immediately after recovery from chloroform it was observed that he had left hemiopia. Little, if any, difference of sensibility could be detected on the two sides of the body, nor any muscular paresis. The following day there was still evidence of hemiopia, but it did not persist for more than a day or two.

Second Operation.—Five days after the first operation, the wound of which had completely healed, and the animal being in good health and spirits, the remaining (left) temporal lobe was cut away. In both cases the removal was very complete, as was shown on *post-mortem* examination.

Results.—These severe operations were recovered from with marvellous rapidity, the animal appearing perfectly well even so early as the day after the establishment of the second lesion. A remarkable change is, however, manifested in the disposition of the Monkey. Prior to the operations he was very wild and even fierce, assaulting any person who teased or tried to handle him. Now he voluntarily approaches all persons indifferently, allows himself to be handled, or even to be teased or slapped, without making any attempt at retaliation or endeavouring to escape. His memory and intelligence seem deficient. He gives evidence of hearing, seeing, and of the

possession of his senses generally, but it is clear that he no longer clearly understands the meaning of the sounds, sights, and other impressions that reach him. Every object with which he comes in contact, even those with which he was previously most familiar, appears strange and is investigated with curiosity. Everything he endeavours to feel, taste, and smell, and to carefully examine from every point of view. This is the case not only with inanimate objects, but also with persons and with his fellow Monkeys. And even after having examined an object in this way with the utmost care and deliberation, he will, on again coming across the same object accidentally even a few minutes afterwards, go through exactly the same process, as if he had entirely forgotten his previous experiments. His food is devoured greedily, the head being dipped into the dish, instead of the food being conveyed to the mouth by the hands in the way usual with Monkeys. He appears no longer to discriminate between the different kinds of food; *e.g.*, he no longer picks out the currants from a dish of food, but devours everything just as it happens to come. He still, however, possesses the sense of taste, for when given a raisin which has been partly filled with quinine he shows evident signs of distaste, and refuses to eat the fruit.

It is also clear that he still both sees and hears. The field of vision appeared at first somewhat limited, and he also seemed to see somewhat indistinctly, making, for example, one or two unsuccessful attempts to pick up a currant from the floor before finally succeeding. This condition, however, soon passed off. He reacts to all kinds of noises, even slight ones, such as the rustling of a piece of paper, but shows no consequent evidence of alarm or agitation, although his attention is evidently attracted by sounds. Thus he was observed to follow with his head the sound of footsteps passing along the corridor just outside his room, directing his attention to them as long as one could oneself distinctly hear them.

This peculiar mental condition was observed for some weeks, becoming gradually less noticeable. A week after the second operation it is noted that he appears brighter in disposition, and is again commencing to display signs of tyrannising proclivities towards his mate, for which he had been remarkable previously. About this time a strange Monkey, wild and savage, was put into the common cage. Our Monkey immediately began to investigate the new comer in the way described, but his attentions were repulsed, and a fight resulted, in which he was being considerably worsted. The animals were, however, separated and tied up away from one another, but our Monkey soon managed to free himself, and at once proceeded, without any signs of fear or suspicion, again to investigate the stranger, having apparently already entirely forgotten the result of his former investigation.

Two weeks after the second operation it is noted that this Monkey continues to "investigate" objects, but with diminishing frequency and thoroughness. He is either rapidly regaining some of his former experience and memory, or forming altogether new ones. He now takes his food up with his hands, and also pays a more natural attention to his fellows than before. All his senses are acute.

Five weeks after the operation his curiosity has sensibly diminished, and he is slowly regaining his former mercurial temperament, continuing, however, tame.

This Monkey was kept for nearly eight months after the operation. Long before the expiration of that time he had regained full possession of his mental faculties, and became one of the brightest and most intelligent animals that we had experience of, domineering over all the other Monkeys which were kept in the same cage with him. He was shown to and tested before the Physiological and Neurological Societies, and was also seen privately by several eminent neurologists. With regard to this Monkey there was no difference of opinion expressed, but it was universally admitted that all his senses, including that of hearing, were perfectly acute. Indeed, it was eventually impossible to detect any abnormality of the cerebral functions.

The animal eventually died of dysentery, after a short illness.

Autopsy.—With the exception of the large intestine, which is ulcerated and inflamed, all the organs appear healthy. In the brain the whole of the temporal lobe is completely removed upon both sides; the lesion extending quite up to the Sylvian fissure on the outer surface, and reaching to the inner edge of the hemisphere on the under surface. On the right side the lesion does not quite reach the parieto-occipital fissure on the external surface, but on the left side the removal extends quite up to this fissure. A very small piece of the antero-inferior edge of the lobe remains on the left side, but this is undermined and cut off from the medullary centre. No trace of the superior temporal gyrus is left on either side, except a part of the grey matter bounding the Sylvian fissure below, and this grey matter is devoid of its corresponding medullary centre. The brain is shown from each side and from below in Plate 49, figs. 6*a*, 6*b*, 6*c*, and in vertical sections through the anterior, middle, and posterior parts of the lesion in figs. 6*d*, 6*e*, and 6*f*.

Remarks.—This is the most extensive bilateral lesion of the whole temporal region which we have performed. What is most remarkable about it is the *immediate loss* and *ultimate recovery* of the intellectual faculty. On localisation of functions the experiment throws no direct light; what evidence there is being entirely negative. The general bearings of its results will be referred to later on.

VII.

Bonnet Monkey of medium size, ♂.

*First Operation.**—A piece of the skull having been removed near the vertex, the right half of the brain was gently drawn aside, and the middle part of the gyrus fornicatus was scooped away. In spite of the greatest care being taken, the marginal convolution suffered a little injury in the attempt to get at the subjacent gyrus fornicatus.

* The first and second operations were performed by me, before the commencement of our joint investigation.—E. A. S.

Result.—The immediate result of the operation is to produce anæsthesia, partial in some parts, complete in others, over the whole left side of the body. The left arm, from the elbow downwards, retains, however, its sensibility. The rest of the arm, the trunk, and the leg have very little, if any, sensibility; for the most part there is no reaction either to a touch or the prick of a pin, but sometimes the latter produces a slight movement, unaccompanied however by the general wincing which is produced by a prick on the right side of the body. The leg is slightly, but perceptibly, pained. This condition continued, with a very slight and gradual improvement, for about seven weeks, when a second operation was undertaken.

Second Operation.—This consisted in the resection of the whole of the right temporal lobe, including the hippocampal region and the hippocampus.

Result.—No noticeable effect followed the second operation. The previous anæsthesia was maintained, but not perceptibly increased; and, although the gradual improvement before alluded to continued to progress, a difference of sensibility upon the two sides of the body (except in the arm, below the elbow) was still manifest eight months after the first operation. It was now decided to establish a lesion upon the opposite side of the brain.

Third Operation.—The left superior temporal gyrus was exposed, and after being tested by faradic excitation its grey matter was extensively destroyed by actual cautery.

Results.—The results of this third operation were practically *nil*. The animal suffered from some epileptiform attacks on the day after the operation, but had recovered on the third day, and showed no difference from his previous condition. Hearing tested, and found to be very acute.

Fourth Operation.—It was next determined to explore the right side of the brain, and to destroy completely any part of the right superior temporal gyrus that might perchance have been left from the second operation. This was accordingly done five days after the third operation. On reflecting the skin and membranes it was found that the superior gyrus had been very completely removed, except 1 or 2 millims. of the superior and posterior extremity. This produced no reaction on being faradized, and might be concluded to have lost its functions. The actual cautery was however applied to it and to the anterior inferior extremity of the lobe, a little of which was also left.

Result.—Three hours after the production of this fourth lesion, the Monkey having recovered from the immediate effect of the operation and of the anæsthetic employed, his hearing was again tested and still found to be very acute, his attention being immediately directed even to small noises such as a kissing or sucking noise made with the lips, clinking of coins, or the rustling of paper.

Subsequent testing at intervals during the next few days having revealed no further symptoms, the Monkey was killed twelve days after the last operation.

Autopsy.—On the right side of the brain the middle part of the gyrus fornicatus

has disappeared, and the corresponding part of the marginal gyrus is somewhat depressed and injured. Almost the whole of the temporal lobe is removed. A narrow strip on the under surface of the occipital lobe has undergone softening and disintegration. On the left side the superior temporal gyrus is destroyed, except its lower (anterior) extremity (tip of the lobe). The surface of the brain just above and in front of the Sylvian fissure has been slightly injured. The brain is shown in Plate 50, figs. 7*a*, 7*b*, and 7*c*.

Remarks.—The first two operations, viz., on the gyrus fornicatus and on the temporal lobe and hippocampal region of the right side, may be looked upon as a continuation of the experiments upon the limbic lobe which have already been published,* and of which they form a complete corroboration. But none of those cases were kept alive with continuation of the symptoms for so long a period as this one.

Otherwise, the Monkey affords another instance of an extensive bilateral lesion of the superior temporal gyrus with complete retention of auditory perceptions.

VIII.

A fair sized but rather ill-nourished Jew Monkey, ♂.

Operation.—Complete resection of the left occipital lobe. The operation was performed under chloroform alone (without the morphia which we have often given in addition) and was quite clean and bloodless.

Result.—The sight was tested about an hour after the establishment of the lesion, and it was found that there was complete right hemiopia, no objects on the right side of the mesial visual plane being seen, although on passing them across the mesial plane they are at once observed.

The next day and repeatedly after that the test was applied, and always with the same result. When each eye was successively covered with adhesive plaster the right half of the retina of the uncovered eye was still found to receive and convey visual impressions to the sensorium, but the images of objects falling upon the left half of the retina produced no impression. The exact boundary of the hemiopia could not be determined, but the above is true as a general statement.

There was no loss of sensibility of the cornea of the opposite eye, nor any paresis of the ocular muscles.

The animal was kept for eight months without any sign of recovery from the hemiopia. It was repeatedly shown both to occasional visitors interested in cerebral physiology and also to the Neurological Society. There was never any difficulty in exhibiting its defect. Although greedily fond of raisins, the animal could never see or seize one until it had been brought so that its image fell upon the right half of one

* HORSLEY and SCHÄFER, 'Phil. Trans.,' B, 1888.

or both retinas. There was no attempt to avoid a threatened blow, aimed from the right side, although when such a threat was made from the other side the animal invariably winced and endeavoured to evade it. When placed on a floor strewn with currants the Monkey invariably picked up only those which lay on the left side of his mesial visual plane, and this caused him to be turning constantly round towards the left as the nearer ones were exhausted. Moreover he was apt, when driven, to knock against obstacles which lay on the right-hand side of his course. Finally, about eight months after the operation, it was determined to kill the animal and examine the brain. This determination was arrived at partly on account of the fact that the animal had for some few weeks been losing flesh, and it was feared that he might not in any case survive much longer. But, prior to carrying out the decision, it was thought advisable to examine the eyes carefully with the ophthalmoscope, and for this purpose we obtained the experienced co-operation of Mr. J. TWEEDY, the Professor of Ophthalmic Surgery in University College. Apart, however, from a general pallor, due probably to anæmia, there was little definite change. "The inner half of the right disc is, perhaps, a little paler than the corresponding half of the left, but compared with those of healthy Monkeys both discs are decidedly pale, with very little of the pink stippling characteristic of healthy nerve."

Autopsy.—The cause of the wasting and anæmia seems to be the presence of numerous worm-like parasites in the lungs. The left occipital lobe is exactly and entirely removed. All the rest of the brain appears perfectly healthy, even the angular gyrus and the other parts next the occipital lobe being quite intact. The cut surface looks as if the incision and removal had been made at the autopsy instead of during life and eight months previously. The appearance of the brain from above is represented in Plate 50, fig. 8.

Remarks.—This is in every way a definite and satisfactory experiment. The lesion is limited to the one occipital lobe, the whole of which is involved. The resulting hemiopia is well-marked and persistent.

IX.

Small Jew Monkey, ♂.

Operation.—Bilateral resection of the occipital lobes.

Result.—Complete and permanent blindness. The eyes at first have a protruding staring appearance, but this is not persistent, and after a few days they appear normal. This animal does not seem to see any objects, however large. When released runs against all obstacles in his path, but after a time learns to grope his way about the room. Can only find his food by groping for it. Although very wild and timid, makes no attempt to evade a threatened blow, but when touched even in the lightest manner flies away displaying great alarm. If a raisin is dropped near him gropes about for it, but cannot see it even if placed on a sheet of white paper. Hearing and

other senses appear very acute. The corneæ retain their full measure of sensibility, and there is no paresis of any of the ocular muscles. Although absolutely unable to see ordinary objects or to form any appreciation regarding them by aid of the visual sense, it is not quite easy to decide whether he is able to distinguish between light and darkness; for, when a large object such as a tray is held between him and the light, he will sometimes put up his hand as if to touch it. He does not, however, always respond in this way, and it is possible that the object may be appreciated by other senses than that of sight; for when a strong light is suddenly flashed upon him his attention is not diverted towards it. The animal was examined ophthalmoscopically by Mr. TWEEDY eight months after the operation, who reports nothing abnormal with the exception of a "slight effusion along the perivascular sheaths, possibly indicative of increase of the subarachnoid fluid."

This animal was kept in good general health, and with no apparent abatement of the blindness, for more than nine months. Before killing him for the purpose of examining the condition of the brain it was determined to test him as thoroughly as possible, so as to decide whether there was any discrimination between light and darkness. For this purpose he was placed in a dark room, and through a hole in a shutter a beam of direct sunlight was admitted, and intermittently flashed upon his eyes from a mirror. Whether the flashes were allowed to follow one another rapidly or slowly, or whether the light were kept directed straight into his pupils, the result upon the behaviour of the animal was absolutely *nil*. Other Monkeys under like circumstances directed their attention towards the mirror when the light was alternately flashed upon them and immediately removed; and when it was kept directed towards them avoided the glare. The conclusion appears therefore unavoidable that, so far as the perceptive faculties are concerned, this animal was totally blind. It is scarcely necessary to say that the pupils reacted to light in a normal manner. The movements of the eyeballs also seemed to be quite natural, so that, although the animal exhibited a somewhat characteristic vacant stare, the blindness could not have been guessed at merely from the appearance of the eyes.

Autopsy. Condition of the Brain.—Both occipital lobes are exactly and completely removed. The angular gyri, which are very well developed in this Monkey, are intact, except that a little of the grey matter in the depth of the external parieto-occipital fissure is cut off. The lesion extends below a short distance forwards on to the under surface of the temporal lobe in both hemispheres. There is no sign of any old inflammatory condition either of these or of any other portions of the cortex.

The brain is represented in Plate 50, fig. 9.

X.

Small Jew Monkey, ♂.

Operation.—Resection of both occipital lobes.

Result.—The blindness is not so complete in this case as in the last. Even the day

after the operation he appears to have a dim perception of objects held between his eyes and the light. Cannot, however, find a raisin placed on a sheet of white paper, and gropes about much in the same way as the other. There is no diminution of sensibility in the corneæ, nor any paresis of the ocular muscles.

This animal was kept alive for several months, and the permanent effects of the operation, which persisted during the whole of that time, were as follows:—

There is no visual perception for objects which lie below the horizontal plane through both visual axes. Above this plane there is some visual perception, but it is very indistinct. It is more distinct for things above and on the right side than elsewhere. Objects, such as raisins, strewn upon the floor are only found by groping. A threatened blow aimed from below is not noticed, but from above or from either side and above it is winced at.

This Monkey remained in apparently good health for about eight months, being eventually killed for the purpose of examining the brain.

Autopsy. Condition of the Brain.—The occipital lobes are entirely removed (fig. 10*a*) with the exception of a small portion of the external surface of the right lobe, which persists to the extent shown in fig. 10*b*, Plate 50. The lesion involves a little of the under surface of the temporal lobe, but less than in Monkey No. 9. The angular gyri are intact, and all the rest of the brain appears perfectly normal.

Remarks.—It is noteworthy that in this animal, as compared with the last, a very small portion of one occipital lobe was left, and that the retention of this small portion of the external border of the lobe was accompanied by retention or re-acquisition of visual perceptions for objects falling upon a certain limited part of the retina.* The significance of this fact will be afterwards alluded to.

XI.

Small Jew Monkey, somewhat weakly, ♂.

Operation.—Bilateral destruction of the superior temporal gyrus.

Result.—On testing the hearing it is found that the animal reacts even to small noises, invariably looking up when paper is crumpled near him. This Monkey suffered considerably from shock, and for the day or two after the operation remained in a stupid lethargic condition, refusing food. He began to rally on the third day, and to give distinct attention to slight sounds, such as the snapping of the fingers near his head. On removing the dressing it was found that the skin had not completely united, but it was re-dressed, and a dose of morphia was given to quiet the animal and prevent his attempting the removal of the dressing. The morphia, however, proved fatal, the effect of shock having probably been increased by the administration of that drug.

* Compare MUNK, *op. cit.*, p. 39.

Autopsy.—Both superior temporal gyri are completely removed.

There is no sign of extension of inflammation, the rest of the brain appearing perfectly healthy.

The brain is shown in Plate 50, figs. 11*a* and 11*b*.

Remarks.—This experiment, although not successful so far as the prolonged maintenance of life after the production of the central lesion was concerned, is complete so far as relates to the supposed exclusive relation of the superior temporal gyri to the auditory functions, for there was no question of a doubt that the attention of the animal was roused even by slight noises after the entire destruction of both those convolutions.

XII.

Large vigorous *Rhesus* Monkey, ♀.

First Operation.—The left superior temporal convolution was completely scooped out, so that not only was the grey matter on the outer surface removed, but also that in the Sylvian and parallel fissures and the white matter of the convolution.

Result.—The animal rapidly recovered from this operation without any appreciable symptom.

Second Operation.—On the tenth day after the first operation the right superior temporal gyrus was removed in the same manner and as completely as the left had been.

Result.—As soon as the animal was recovered from the effect of the anæsthetic her hearing was tested, and, although still somewhat lethargic, she was found to give attention even to slight sounds, such as kissing or sucking noises made with the lips. This was repeatedly tried, and she invariably responded by looking up.

This Monkey made a rapid recovery; indeed the double operation produced no perceptible effect upon its general health. But the creature shows the same change of disposition that was manifest in Monkey No. 6. She appears to have lost, in great measure, intelligence and memory. She investigates all objects, even the most familiar, as if they were entirely unknown, tasting, smelling, and feeling all over everything she comes across. She is tame, and exhibits no fear of mankind, but shows uncontrollable passion on the approach of other Monkeys, so that it is now necessary to shut her up in a cage by herself. Like Monkey No. 6, she now invariably devours her food by putting her head down to the platter, instead of employing the hands to convey it to her mouth. Moreover, her appetite is insatiable, and she crams until her cheek-pouches can hold no more. She evidently still sees, hears, tastes, and smells perfectly well, but her understanding of the impressions which she derives from her senses is unquestionably small. Cutaneous sensibility shows no appreciable diminution.

The peculiar idiotic condition into which this Monkey was thrown by the operation was more persistent than in the case of No. 6. Recovery proceeded but gradually;

and, although in many points improvement was manifest, there was never, during the whole time that the animal was kept, that complete return of intelligence which was observed in No. 6 (which had, it will be remembered, a much more extensive bilateral lesion). Her appearance remains stupid, and her movements lethargic; she is still savage towards her fellow Monkeys; her attention is not easily attracted, either by sights or sounds, although an abrupt movement or a sudden and unusual noise will produce signs of perception. She usually takes her food up with her hands, but is still markedly greedy, taking, when she can get it, much more food than a normal Monkey of the same size.

After being kept under observation for more than eight months, during which she was exhibited to numerous visitors and to the Neurological Society, the animal was killed and the brain examined.

Autopsy.—Both superior temporal gyri are completely removed, and their place is occupied by a large fissure in which the island of REIL can be seen. The rest of the brain is, to all appearance, normal.

The brain is shown in Plate 50, figs. 12*a* and 12*b*.

Remarks.—What is most remarkable in this case is the fact that a comparatively limited bilateral lesion of the cerebral surface should have produced so considerable a change in the general cerebral functions. The case of Monkey No. 6 is far less striking in this particular, because the bilateral lesion *there* was very extensive; moreover, the loss of intelligence was far less persistent, although at first not less distinct.

The experiment is quite conclusive against the localisation of auditory perceptions in the superior temporal gyri alone. In this case there was certainly no trace remaining of either convolution, and the animal could unquestionably hear, even slight sounds. Whether the appreciation and discrimination of sounds remained the same is a point which, it must be admitted, it is hardly possible to solve satisfactorily by experiments on animals. But in this case, at least, even if it had been possible (which it was not) to prove that the discrimination of different sounds was abolished or diminished after the lesion, such abolition or diminution must still be looked upon merely as one of the manifestations of the general idiocy which was produced by the operation rather than as due to the interference with any special auditory function of the part.*

XIII.

Vigorous *Rhæsus*, ♂.

Operation.—The whole of the left angular gyrus, to a depth of 6–7 millims., was scooped away, the removal being completed up to and including the grey matter in the fissures bounding the convolution.

* The extensive character of the lesion of the superior temporal gyrus in this case, and also in that of Monkey No. 6, having been called in question by Dr. FERRIER (*Vide* Article in 'Brain,' April, 1888), I have caused photographs of these two brains, and of sections across them, to be made, and intend to publish these photographs in the succeeding number of 'Brain.'—[E. A. S., June 18, 1888].

Result.—The immediate effect of the operation was to produce hemiopia, the left side of both retinæ being apparently blind. This condition lasted for a few days, but gradually passed off, so that no visual disturbance could after a time be detected. The animal is still alive and well (November, 1887), eight months after the operation. There has never been any deficiency of sensibility in either eyeball, nor any paresis of the muscles moving either the eyeball or the eyelid.

General Remarks.

With the exception of one experiment upon the gyrus fornicatus, the results which we have here recorded bear entirely upon the functions of the temporal and occipital lobes and of the angular gyrus; and our object in undertaking them was to decide, if possible, between the conflicting results of preceding experimental observers, and especially those of FERRIER, MUNK, and LUCIANI and TAMBURINI.

In the first edition of his elaborate work on the ‘Functions of the Brain,’ published in 1876, FERRIER gave a clear and succinct statement of his views upon the functions of these parts, based for the most part on experimental investigations, carried out chiefly upon Monkeys, which had been published by him *in extenso* in the ‘Philosophical Transactions.’ To the views there enunciated we need not, however, specially refer, because they have been in some measure modified and superseded by the author’s more recent utterances in the second edition of the book, which was published only last year, and have therefore come to possess merely a historical interest in connexion with the development of the general question of localisation of functions in the brain. Between the appearance of the first and second editions, Dr. FERRIER undertook, in conjunction with Professor G. YEO, a renewed investigation into the functions of these and other parts of the Monkey’s brain; and their results, which are given in full in the ‘Philosophical Transactions’ for 1885, are embodied in the later edition. We may take it, then, that the mature judgment of the author is set forth in the second edition; and it is with the views which we there find that we propose to deal.

The experiments of MUNK, mainly on Dogs but also on Monkeys, have been published from time to time in the ‘Verhandlungen der Berliner Physiologischen Gesellschaft’; and these papers have been collected by the author, and re-issued in a separate form.* It is to this collection that we shall chiefly refer in alluding to MUNK’s views regarding the functions of the parts we have been dealing with.

The results obtained by LUCIANI and TAMBURINI are detailed in two communications, “Sulle Funzioni del Cervello,” 1878 and 1879, of which excellent critical digests are given in ‘Brain,’ vols. 1 and 2; whilst the results of later experiments by LUCIANI alone are given by himself in a more recent number of the same periodical (‘Brain,’ vol. 7, “On Sensorial Localizations in the Cortex Cerebri”).

* H. MUNK, ‘Gesammelte Mittheilungen aus den Jahren 1877–80.’ Berlin, 1881.

We will consider first of all our experiments upon the occipital lobe, because the results yielded by them are definite and positive, whereas our results regarding the other parts which are the subject of this paper have been mainly negative.

We record three experiments upon the occipital lobe,* one being unilateral and the other two bilateral. In the unilateral case, and in one of the bilateral, the lesion was practically confined to that lobe, and at all events did not involve the angular gyrus. In the third case the grey matter of that gyrus in the depth of the parieto-occipital fissure is slightly injured. In all three the superficial lesion extends a short distance on to the under surface of the temporal lobe. In the unilateral operation (Case No. 8), in which only one of the occipital lobes was removed, the operation was followed by immediate and persistent blindness for all images falling upon the corresponding half of each retina (bilateral homonymous hemianopsia). In one of the bilateral operations (Case No. 9) the establishment of the lesion was followed by complete and persistent blindness of both eyes. In the other bilateral operation (Case No. 10) the blindness which was produced, although quite persistent, was not so complete as in the other; but images which fell upon the lower part of the retinae were still capable of producing impressions, whether distinct or not it is impossible to say, which were transmitted to, and perceived by, the brain. In this case, however, it was found that a very small part of the occipital lobe had escaped removal, so that it does not fall, like the other two, into the category of experiments in which the whole lobe of one or both sides was entirely removed.

The two experiments in which the ablation respectively of one and both occipital lobes was complete are entirely confirmatory of the statements of MUNK on this point, who asserts that complete and permanent blindness is produced by removal of the occipital lobes alone, without the implication of the angular gyri,† and that removal of one occipital lobe causes complete and permanent hemianopsia. LUCIANI obtained the same *immediate* result, but the blindness was not persistent; moreover, he states that the result is not confined to lesions of this lobe, although better marked and more persistent when it is included in the lesion. HORSLEY and SCHÄFER‡ also obtained either entire blindness or hemianopsia, according as the operation upon the occipital lobe was bilateral or unilateral, only as a *transitory* condition; but in the cases they have described the result of *post-mortem* examination showed that the removal of the occipital lobes was never quite complete. In one case in which, after an incomplete destruction of both occipital lobes, which had been followed by the

* Really four, but one (Case No. 2) need not be referred to here, since the animal was not kept long enough to judge of the persistence of the hemiopia produced.

† MUNK remarks (p. 39), "After a time, and very gradually, the sight somewhat improves;" but the only evidence of this appears to be that the animal can move about slowly without knocking against obstacles.

‡ *Op. cit.*

usual result obtained in such cases—viz., at first total blindness, followed after a few days by a considerable amount of recovery—subsequent destruction of the angular gyrus of one side caused hemianopsia which appeared permanent. But there is reason to believe that the permanent blindness in this case was due, not to the lesion of the angular gyrus, but to the fact that, in removing this convolution, a part of the occipital lobe which had been left from the first operation was also removed. The temporary complete blindness which often follows even incomplete ablations of the occipital lobe is easily understood, if we remember that the immediate effect of such ablations may extend to the parts of the lobe which are not actually involved in the removal—a temporary disturbance of their function being produced by the interference with the circulation in the adjoining parts, owing to the occlusion of the blood-vessels of the ablated portion, and also by the removal of the support which they naturally obtained from that part whilst still *in situ*. These conditions of disturbance soon remedy themselves, but while they last they must affect the functions of the parts which are thus disturbed.

Our present results are at variance with those of FERRIER, who denies that the removal of the occipital lobes alone is followed by any, even temporary, deficiency of vision. We may remark, however, that in the cases of which figures are published by FERRIER, either of his own experiments or of those which he performed in conjunction with Professor YEO, the occipital lobe is in none shown to be completely removed; on the contrary, in some little more than the cauterisation of the external surface has been attempted, and in all the others considerable portions of the lobe are left. This amount of lesion might very well be accompanied by the retention of so much visual perception that it might be difficult or impossible to recognise in animals any functional defect. This, at least, is the only way in which we can reconcile the discrepancies between the results of FERRIER and YEO, on the one hand, and those of MUNK, of LUCIANI and TAMBURINI, of HORSLEY and SCHÄFER, and of ourselves, on the other hand. These two experiments, viz., those in which the occipital lobe was totally removed, (1) unilaterally, and (2) bilaterally, appear to afford a complete demonstration of the idea that in the cerebral perception of visual impressions that lobe, and that lobe only, of the cerebral hemisphere of the Monkey is concerned. They must, of course (to arrive at the whole of this conclusion), be taken in conjunction with other experiments in which uni- or bi-lateral lesions have been established by ourselves and by previous investigators in other parts of the cortex. Certainly in our hands, and in the very numerous experiments of HORSLEY and SCHÄFER, we have not found in any single instance in which the occipital lobe has not been involved in such lesions any but the most transient influence exerted upon the visual functions (except in those cases like our Nos. 6 and 11, in which, from the situation or extent of the injury, a general depression of the cerebral functions has resulted, and a condition resembling idiocy has been established).

We have made one or two experiments with the view of testing the assertions of MUNK regarding the connexion of the several parts of the visual receptive surface—the retina—with parts of the visual perceptive surface—the cortex of the occipital lobe. But the localised lesions which we have produced, after the more extended disturbance which is temporarily caused by the operation has subsided, have not so far yielded any permanent results that we could in these animals appreciate. We have not found it possible to determine, as MUNK would appear to have done,* the existence of localised central blindness. Indeed, the difficulty of such determination in these animals seems to us to be well nigh insuperable. On account of this difficulty and the necessary incompleteness of those experiments we have not recorded them in this paper, and do not for the present propose to do so. But the third experiment upon this region which we have recorded does certainly favour the idea of such a connexion or projection. In this, a very small part it is true, but still a part, of the occipital lobe of one side remained intact, and the animal, in place of being completely blind, like that in which every trace of the lobe has been removed, retained its visual perceptions, probably imperfect ones, for impressions affecting a part, and a part only, of both retinae. This is the only case in which we were able to substantiate what, for want of a better term, we will speak of as co-related localisation in the occipital lobe; but although it stands singly, it is both positive and well-marked, and affords, therefore, important evidence of the existence of such co-relation in a sensory area.

We will next consider the results which we have obtained from destruction of the angular gyrus. This convolution has attracted a great amount of attention from others as well as ourselves, because it is the part of the brain which was originally believed by FERRIER to be exclusively concerned with the appreciation of visual impressions derived from the opposite eye; and, although this position is somewhat modified in the later edition of his book, it is still regarded as a most important part of the cerebral visual centre, viz., as connected with the appreciation of those visual impressions which affect the yellow spot or centre of direct vision. When examined into, it will, however, be found that this opinion rests mainly upon the fact that a very temporary visual disturbance may follow its destruction or injury. Certainly we have ourselves in one or two cases obtained this result, nor is it to be wondered at if we accept the conclusion that the adjacent occipital lobe is the real cerebral visual centre.

For the effect of operating upon the angular gyrus may, and sometimes does, produce such a temporary disturbance in the adjoining occipital lobe as to depress the functions of this, or even temporarily to abolish them. The same result is often got by operating on the temporal lobe. But the symptoms are not permanent and may

* At least in Dogs.

even be altogether absent, and the result of operating upon this gyrus offers indeed a very striking contrast to the result of removing the lobe behind it.

MUNK* denies the participation of the angular gyrus in visual perception. He alleges that it is connected with the sensibility of the globe of the eye and with the action of the ocular muscles. He states that in Monkeys in which he has excised this convolution the sensibility of the cornea of the opposite eye and also of the whole bulb is abolished, that the lateral movements of the eyes are incomplete, and that there is sometimes slight ptosis and lacrymation.† Our experiments do not in the least confirm these statements. In every case in which we have destroyed one angular gyrus the sensibility of the conjunctiva of the opposite eye has been, so far as we could determine, in no way affected.‡ Not only is the reflex act of winking produced on touching the cornea, but the animal winces in a manner unmistakably indicative of pain. Where both angular gyri have been destroyed the result has been the same for both eyes.

Our experiments upon the temporo-sphenoidal or temporal lobe have been all, with one exception, performed bilaterally, for we very early came to the conclusion that no definite results were to be obtained in Monkeys regarding the senses of hearing, taste, or smell from unilateral lesions of the brain. Roughly speaking, we may class our experiments under two heads: (1) partial or local extirpations of portions of the lobe, (2) complete removal of the whole lobe. The partial extirpations comprised (*a*) the antero-inferior part of the lobe (cases 1 and 2), (*b*) the superior temporal gyrus (cases 1, 3, 7, and 11). They have produced in our hands no appreciable effect, neither loss of taste, smell, nor hearing, and, so far as could be determined in Monkeys, no diminution in the acuteness of any of these senses. Animals with the antero-inferior portion of the lobe, including the subiculum, completely cut away smell their food, immediately detect a malodorous substance, such as aloes or asafoetida, with which it (*e.g.*, a raisin) may have been smeared, and cast it aside without tasting. A raisin into which quinine has been inserted is smelt, eagerly bitten, and immediately rejected with expressions of disgust. Animals with both superior temporal gyri completely destroyed give evidence of the possession of acute powers of hearing; they turn at the slightest rustle, look up at the smallest noise, even immediately after the

* *Op. cit.*, '4te Mittheilung,' pp. 64, 65.

† MUNK mentions that in Monkeys in which he has removed the angular gyri he has noticed, amongst other symptoms, that they employ the whole hand instead of the fingers merely to pick up small objects, and he infers from this that the movements of the eyeballs are interfered with. But it appears to us that such symptoms (which were not noticeable in our Monkeys) may more probably be explained by supposing that the adjacent ascending parietal gyrus, which contains the principal centres for the movements of the fingers, may have become partially involved in the lesion, especially since the operations were not performed antiseptically.

‡ In this point we are in agreement with LUCIANI and TAMBURINI, "Seconda Comunicazione," 'Brain,' vol. 2.

operation and when still drowsy from the prolonged influence of the anæsthetic, and follow with the head and eyes the direction of footsteps along a corridor outside the room in which they are confined. Some of these animals we have had under observation for many months; they have been seen and tested by many people, and the absence of the gyrus has been attested by *post-mortem* examination.

FERRIER and YEO* have published a similar case of destruction of the superior temporal gyrus on both sides of the brain with a result contrary to those which we have obtained. In their case the Monkey was apparently stone-deaf. It reacted to no sounds,† not even to the report of a pistol. The ears did not even twitch at unusual sounds, as they frequently do in Monkeys. It was examined independently by competent observers, and was exhibited at the International Medical Congress of 1881 to the Physiological Section, and no evidence of hearing even the report of a pistol could be obtained. The animal was kept under observation for thirteen months, and showed during all that time no clear evidence of hearing.

There is no doubt that FERRIER was justified by the result of this experiment in inferring that the cerebral localisation of auditory impressions is to be looked for in the superior temporal gyri.‡ But, to our thinking, he was not justified in assuming such localisation without further evidence than that afforded by this single experiment. The matter was of sufficient importance to call for a repetition of the lesion in other Monkeys; and had this been done by him we have no doubt, in view of our own experiments, that FERRIER would have seen reason to modify his too rapid conclusion. In six different Monkeys we have established this lesion, with or without involving other parts of the lobe, and in none of them has hearing been abolished, or even permanently diminished in acuteness.§ This discrepancy between the experiment of FERRIER and YEO and these results of our own cannot be explained by assuming that the lesion was more extensive in their case than in ours. On the contrary, although in one or two of our animals a minute portion of the gyrus was found to have been left, in all without exception, as may be seen by comparing the respective figures, the removal was much more extensive and complete than in the Monkey operated on by FERRIER and YEO, in which, especially upon the right side, a very noticeable amount of the convolution remains (see the figs. of sections across the brain in their paper already

* *Op. cit.*, Experiment 13; and FERRIER, 'Functions of the Brain,' pp. 309, 310.

† This statement is, however, not unmodified. "Occasionally a doubt was raised as to whether the absence of reaction to sounds was absolute." FERRIER, *loc. cit.*, p. 310.

‡ This opinion must be modified since the publication of the notes of this case in a recent number of 'Brain.' (FERRIER: "SCHÄFFER on the Temporal Occipital Lobes." 'Brain,' April, 1888, pp. 13-16.) From these it appears that the Monkey frequently reacted to auditory impressions. The subject will, however, be fully discussed by me in the next number of 'Brain.'—[E.A.S., June 18, 1888.]

§ Dr. FERRIER was good enough to assist us on several occasions in investigating our animals, especially some of those with a double superior temporal lesion; and in all of those which we submitted to him, with one exception, he frankly acknowledged that the perception of auditory impressions

quoted. The photographs of the whole brain in the paper do not exhibit the limits of the lesion distinctly, but it is depicted in figs. 97 and 98, p. 309, of FERRIER'S 'Functions of the Brain.')

We are not, of course, called upon to explain the discrepancy, and can indeed offer no reasonable explanation, unless it be to assume that the Monkey which was selected by FERRIER and YEO for this operation happened, unknown to them, to be already deaf. At all events it would not appear that they put its hearing to the test before operating.* At the same time it must be admitted that there are great differences in perfectly normal Monkeys with regard to their reaction to sounds which they are unaccustomed to connect with any idea of danger. We have frequently observed that Monkeys which have experienced no cerebral lesion whatever will sometimes fail to start or show any sign of hearing at the report of a pistol, whilst others will react very strongly to such a noise. Thus the investigation is beset with difficulties, and it is only by the patient study of each individual and by the multiplication of instances that results to be relied on can be obtained.

One of our experiments (Monkey No. 6) involved the complete removal of the temporal lobe on both sides of the brain. How complete the lesion was is well shown both in the figures and in the casts of the brain.† This is one of the cases in which there was, for a few days after the complete establishment of the lesion, a condition resembling idiocy produced, which, however, gradually passed away, leaving the animal in full and undoubted possession of all his senses. Taste, smell, and hearing were unquestionably present, and not only present, but, so far as could be determined, perfectly acute. The animal was repeatedly tested, and was, along with Nos. 5 and 11, submitted to special examination by a committee of the Neurological Society appointed for the purpose. Not the slightest doubt was possible as to the continued possession of these senses in this animal, and it is therefore not possible to suppose they are *localised* in the part of the brain which had been bilaterally removed. Whether there was any difference between this animal and normal Monkeys in the appreciation of the impressions obtained through those senses is a question regarding which we offer no opinion, nor is it possible, so far as we can see, to form such opinion from experiments upon animals. Considering only such manifestations as we are able to appreciate, the significance of these appears to favour no other conclusion than that at which we have arrived.

remained—that the animals heard. The exception was No. 5, as to the hearing of which we were not able to convince Dr. FERRIER, although we ourselves, from long and accurate observation of the animal, had no doubt whatever that it heard acutely. Curiously enough, it turned out on *post-mortem* examination that in this animal we had mistaken the convolutions, and removed on the left side of the brain the second temporal gyrus, leaving the superior intact.

* Since, as now appears (see preceding note), the Monkey was not really deaf *after* the operation, this argument has become superfluous.

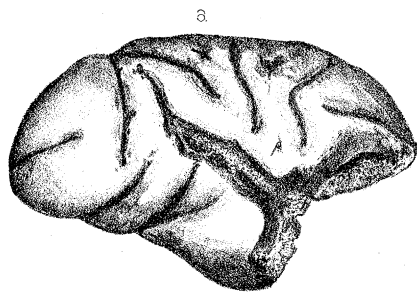
† Casts of the brains operated on are deposited in the Anatomical Museum of University College.

Lastly, we would offer a few remarks upon the two remarkable instances in which a bilateral lesion of the temporal lobe has produced a temporary general depression of the intellectual faculties, and has reduced the animals, for a time at least, to a mental condition resembling that of an idiot. In one of the cases (No. 6) this resulted on the complete removal of both lobes, but in the other (No. 12) on the removal of both superior gyri alone. It must, however, be remarked that in the latter instance the operation was conducted in such a manner as to produce a very profound lesion of that part of the hemisphere. The fissures bounding the gyrus (Sylvian and parallel) were drawn open, and the whole of the convolution, in its entire extent and depth, completely shelled out on both sides of the brain. A very great amount of vascular disturbance was thereby necessarily produced, and this must have affected, for a time at least, other portions of the brain.

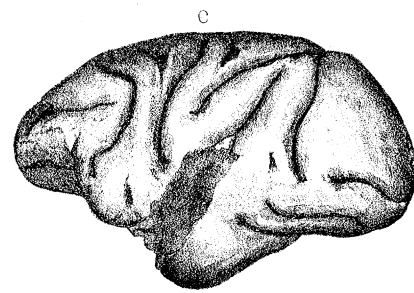
Probably, therefore, the most reasonable explanation of the general depression of the intellectual faculties which these operations produced is to be found in this vascular disturbance. This, without actually causing the complete paralysis of function of the remainder of the cerebrum, which would have been evidenced by motor paralysis, may yet have sufficed to interfere with the active performance of its functions sufficiently to produce the results described. Thus, in both cases the movements were slow, the senses dulled, the memory very defective, and the disposition changed. It would obviously be unreasonable to assume, certainly in the second case, that these alterations are caused by the local lesion, but it appears to us that they may not unreasonably be explained on the hypothesis we have put forward. The gradual recovery of intelligence in both these animals is extremely interesting, and recalls instances which have been recorded in the human subject in which a gradual recovery has taken place after almost total abolition of the intellectual faculties.*

The Arabic numbers attached to the figures illustrating this paper correspond to the Roman numerals in the record of cases. All the drawings have been made by tracing upon a plate of glass placed over the brain (arranged in an appropriate position) the outlines, the sulci, and the exact superficial extent of the lesion in each case. Such tracing has then been transferred to paper and filled in with appropriate shading. The representations of the sections have been prepared in like manner.

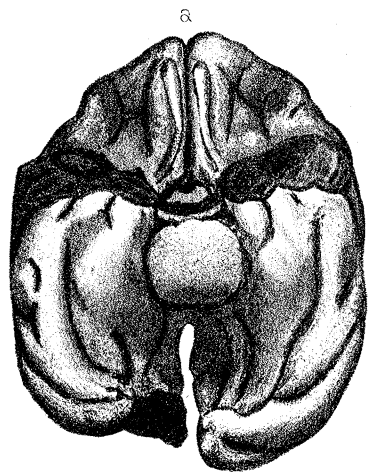
* See for example a case which has been recorded by the late Professor W. SHARPEY in 'Brain,' vol. 2, under the title "The Re-education of the Adult Brain."



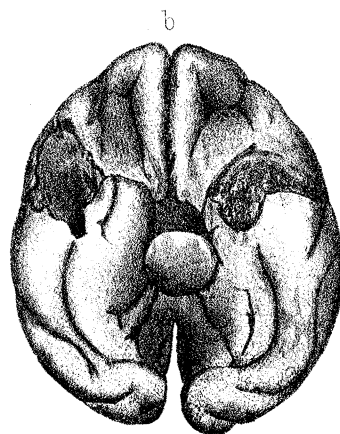
1



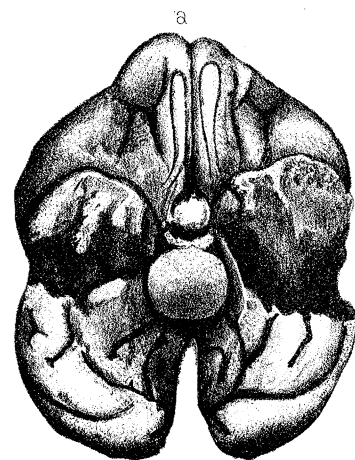
1



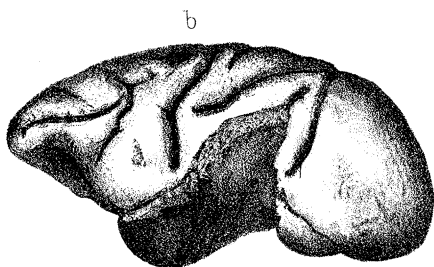
2



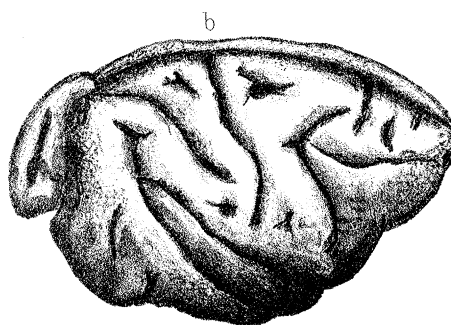
1



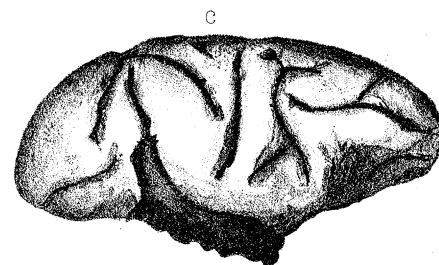
3



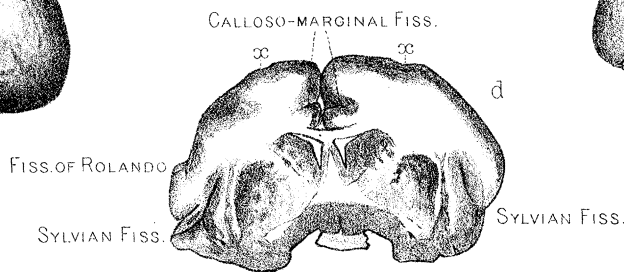
3



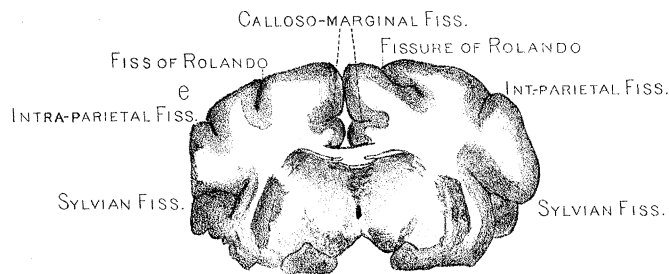
2



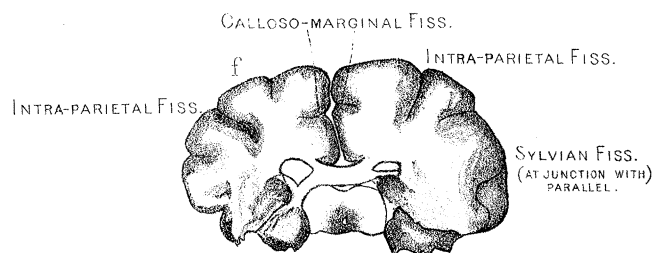
3



3

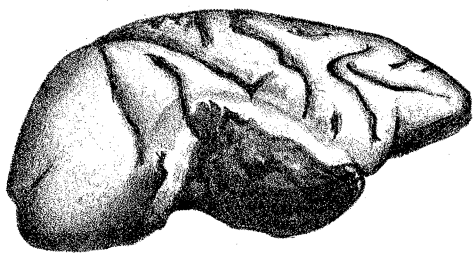

3

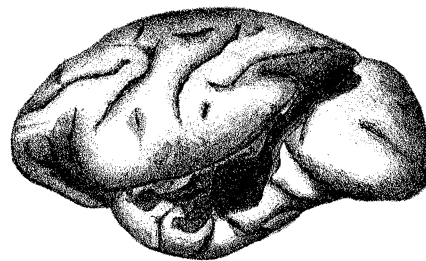

3

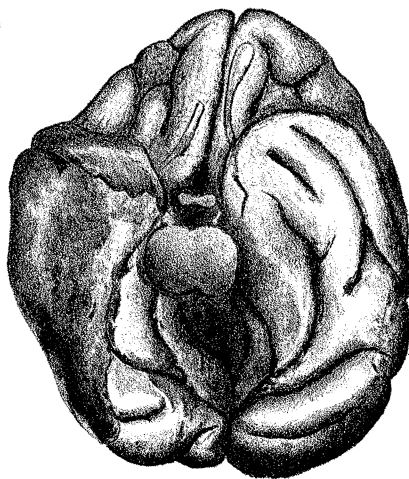
PHILOSOPHICAL THE ROYAL BIOLOGICAL SOCIETY OF TRANSACTIONS OF SCIENCES



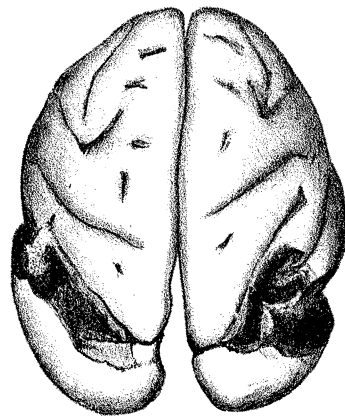
4. a.



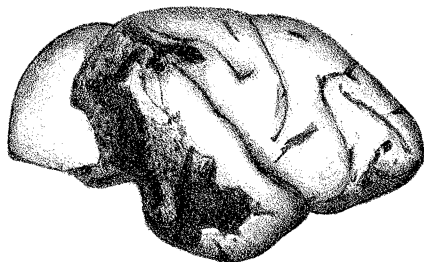
5. a.



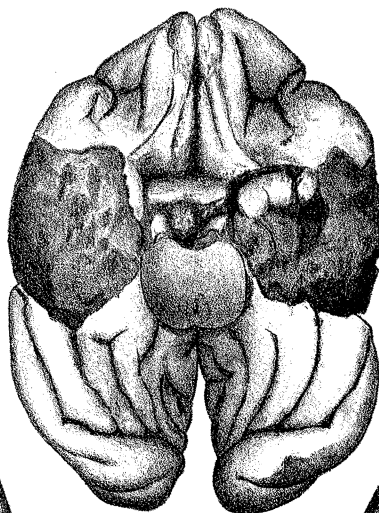
4. b.



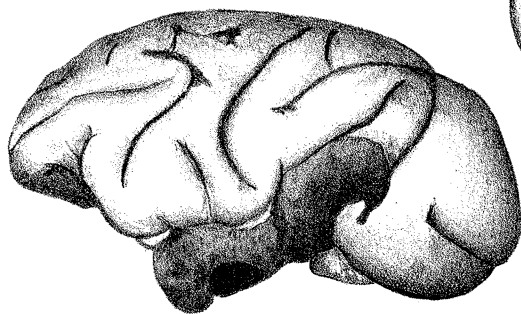
5. c.



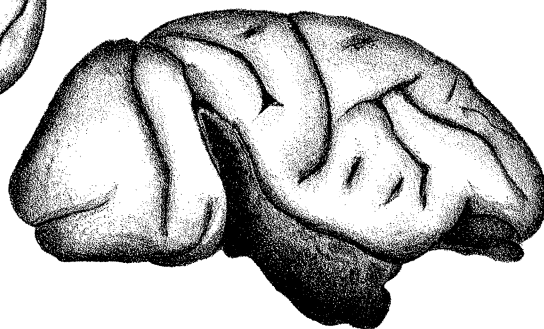5. b.



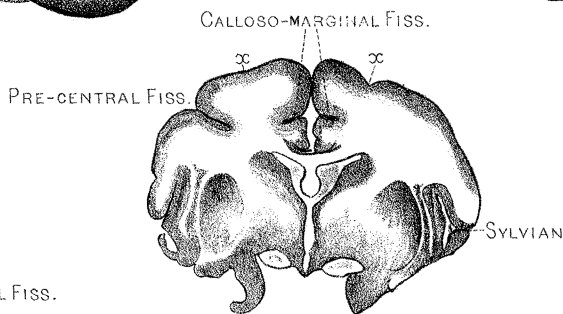
6. c.



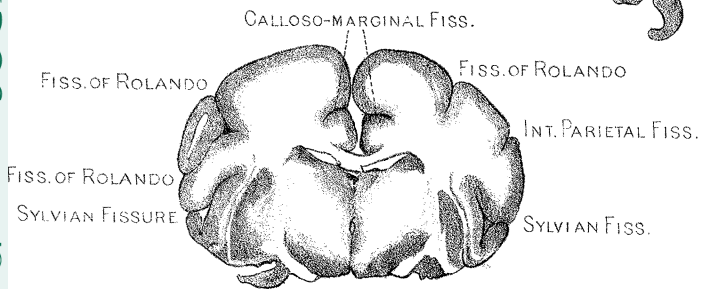
6. b.



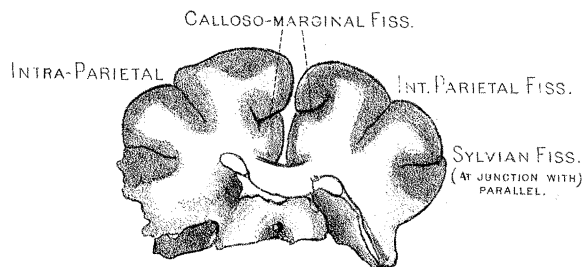
6. a.



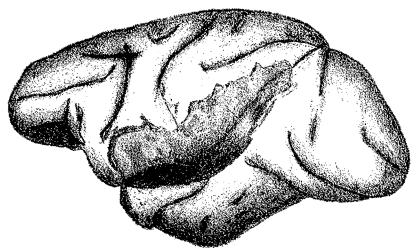
6. d.



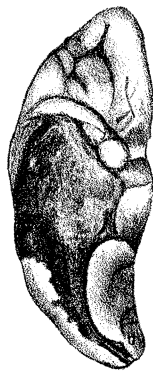6. e.



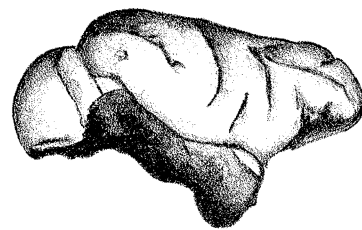
6. f.



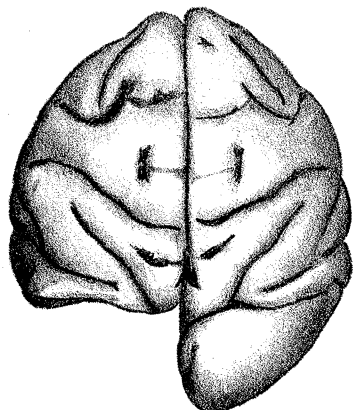
7. a.



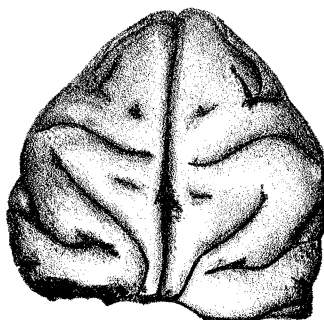
7. c.



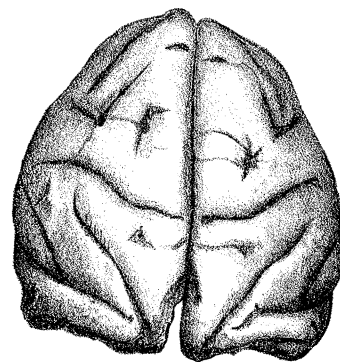
7. b.



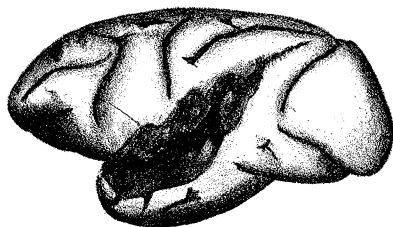
8.




9.



10. a.

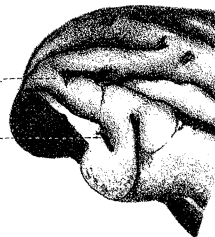

11. b.

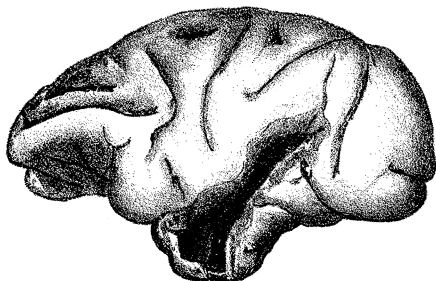


11. a.

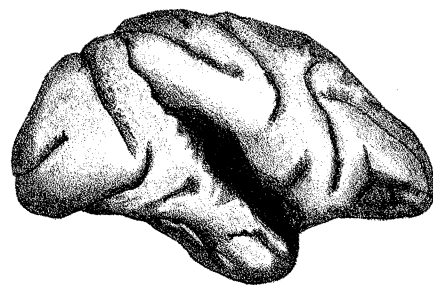
ANGULARGYRUS.--
EXT. PAR. OCCIP. FISS.--



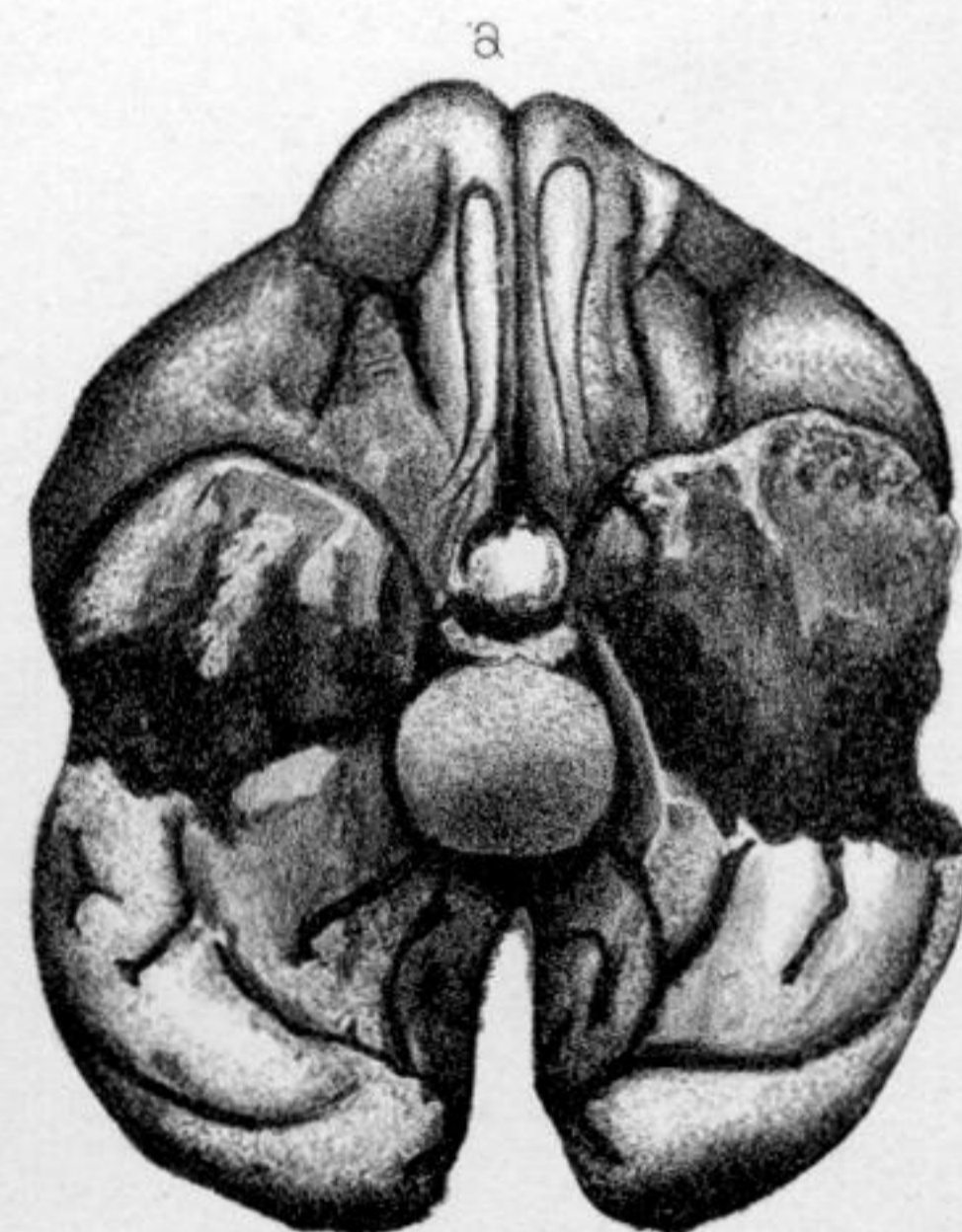
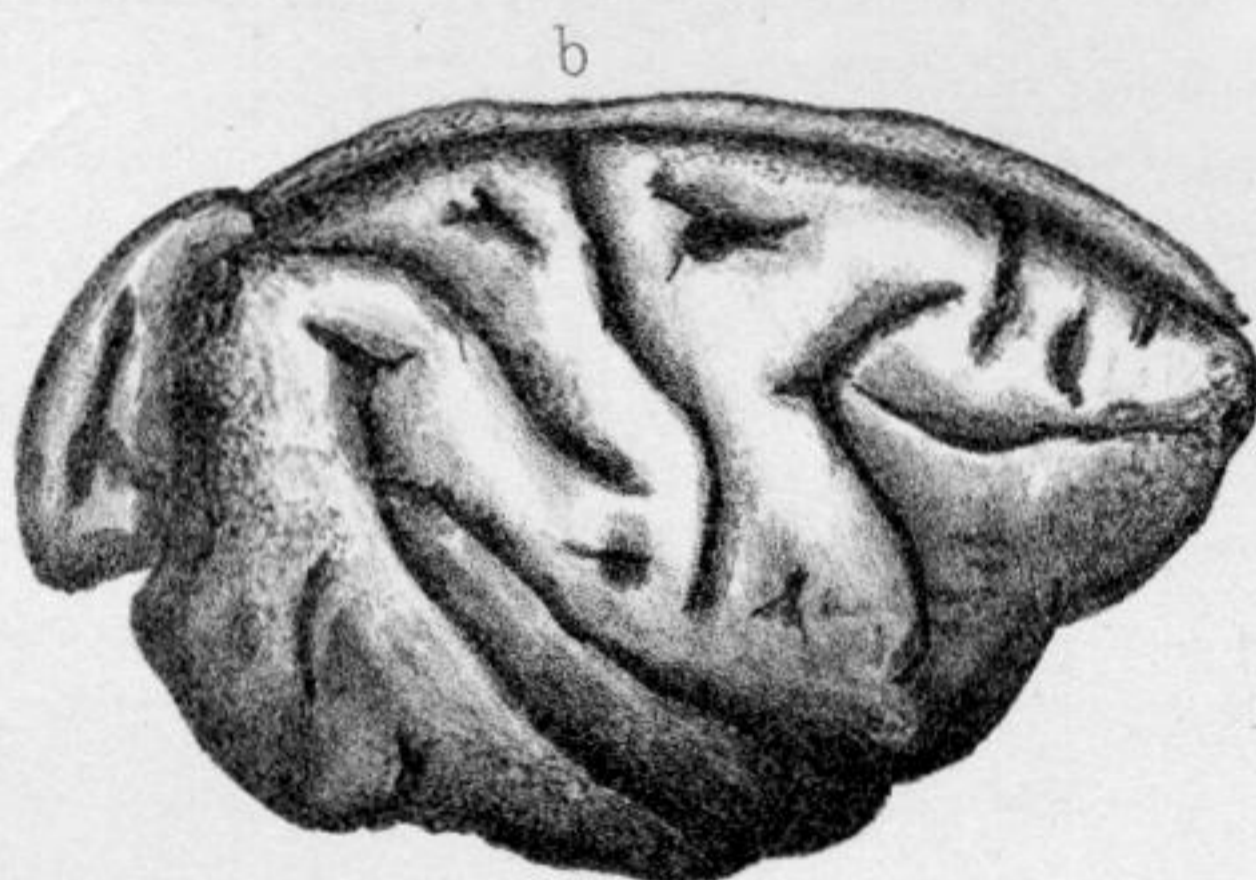
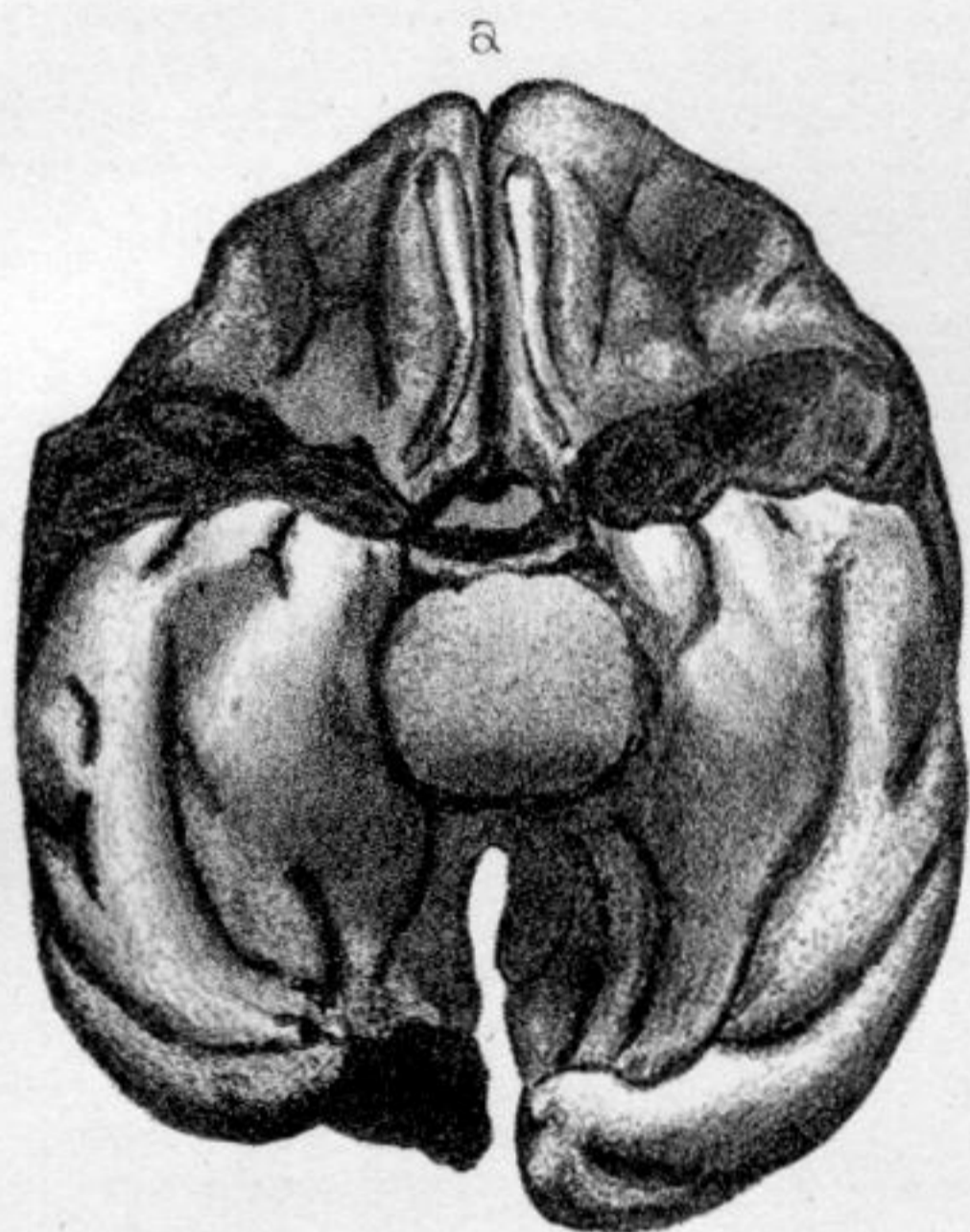
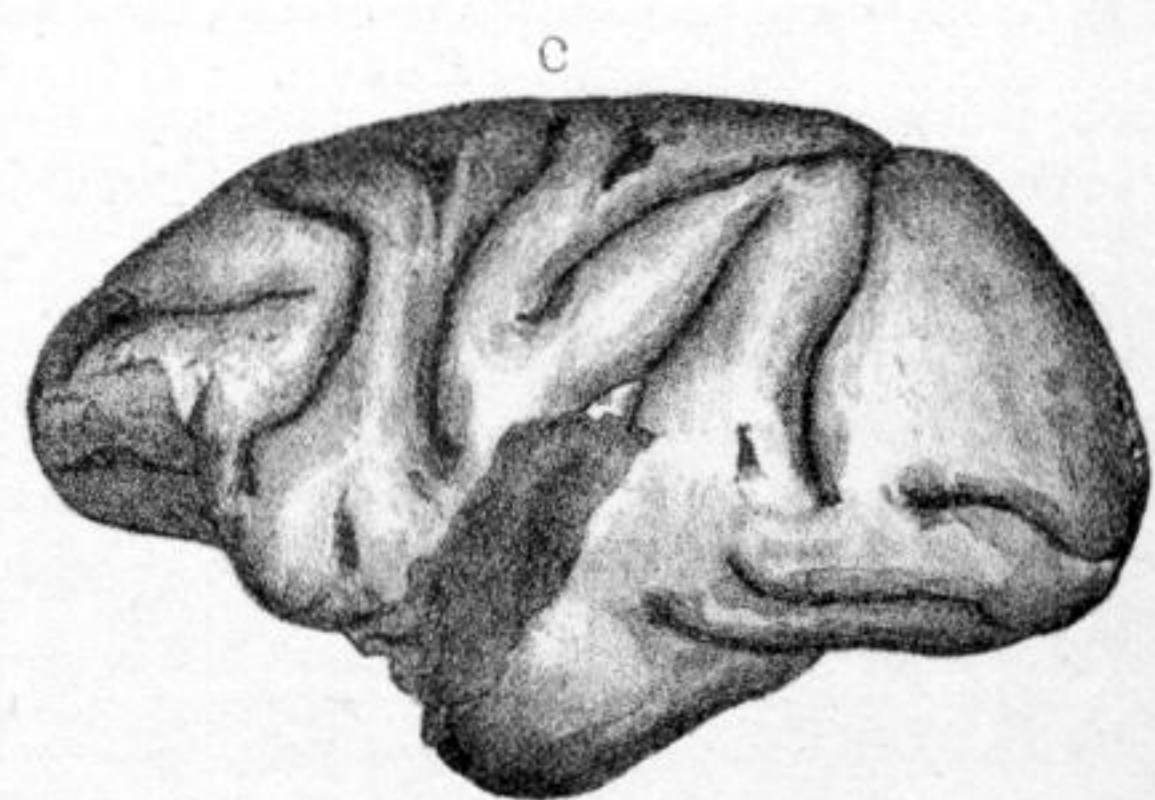
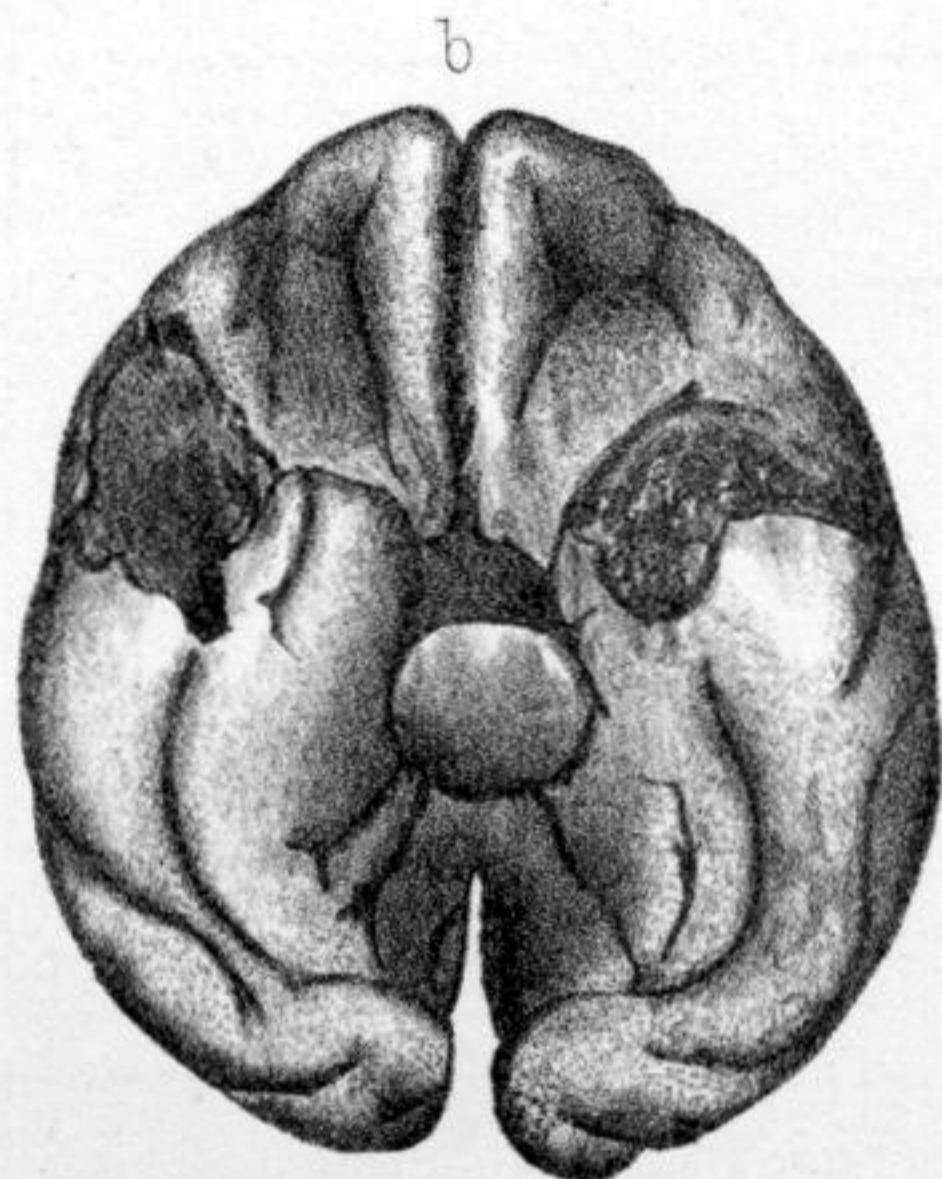
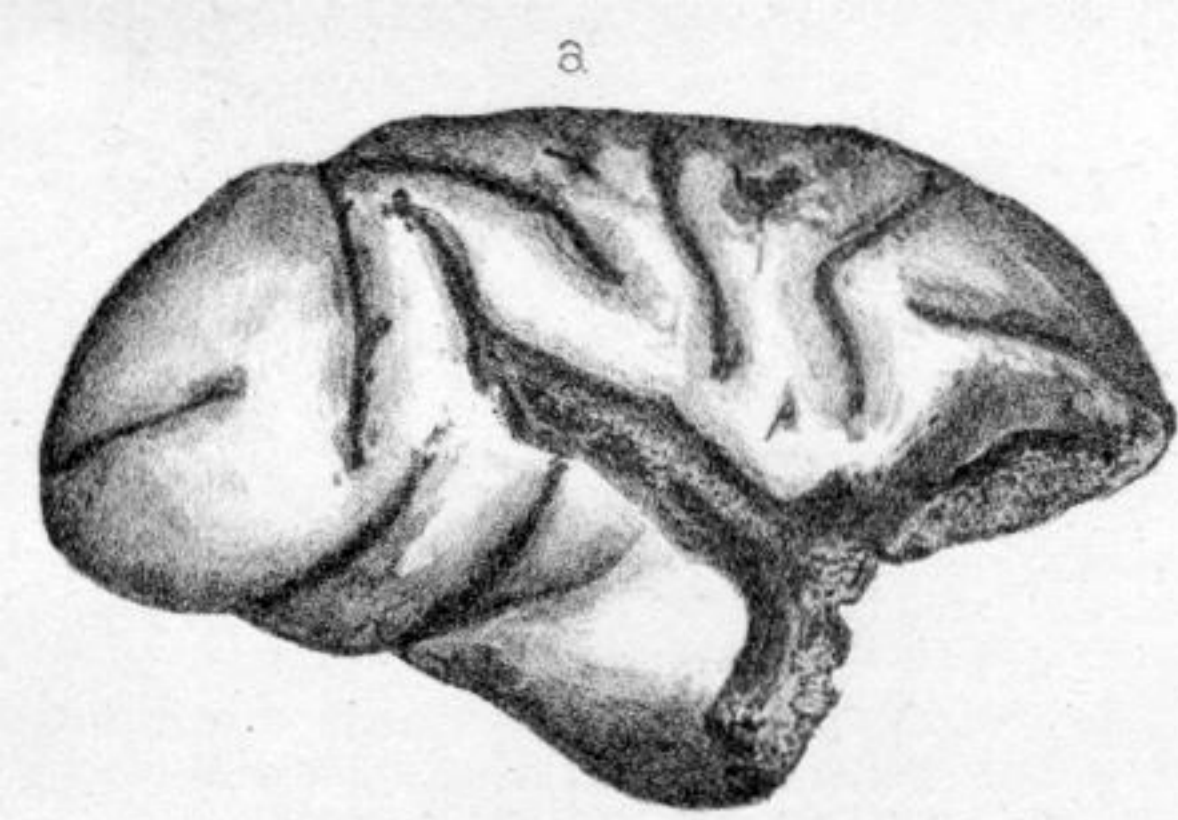
10. b.



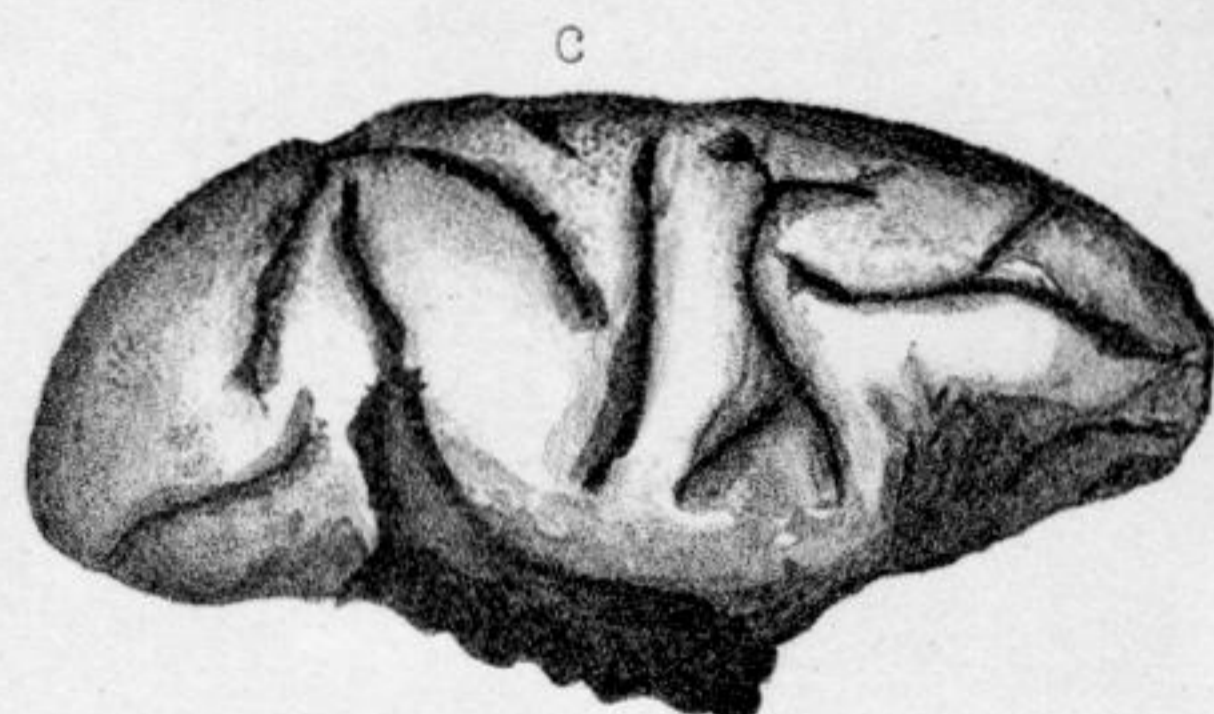
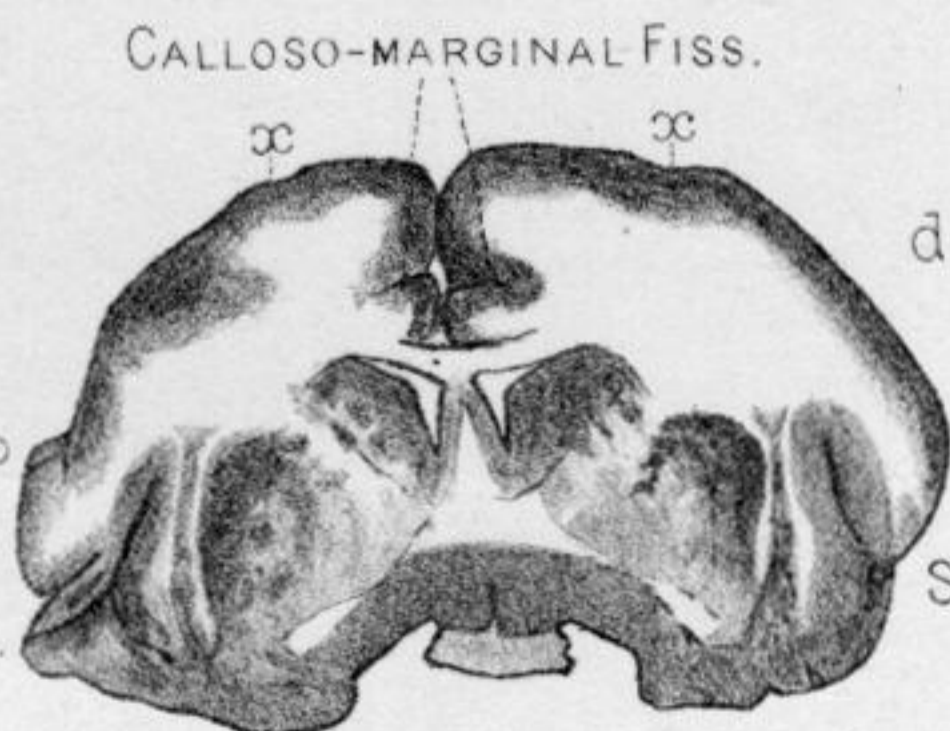
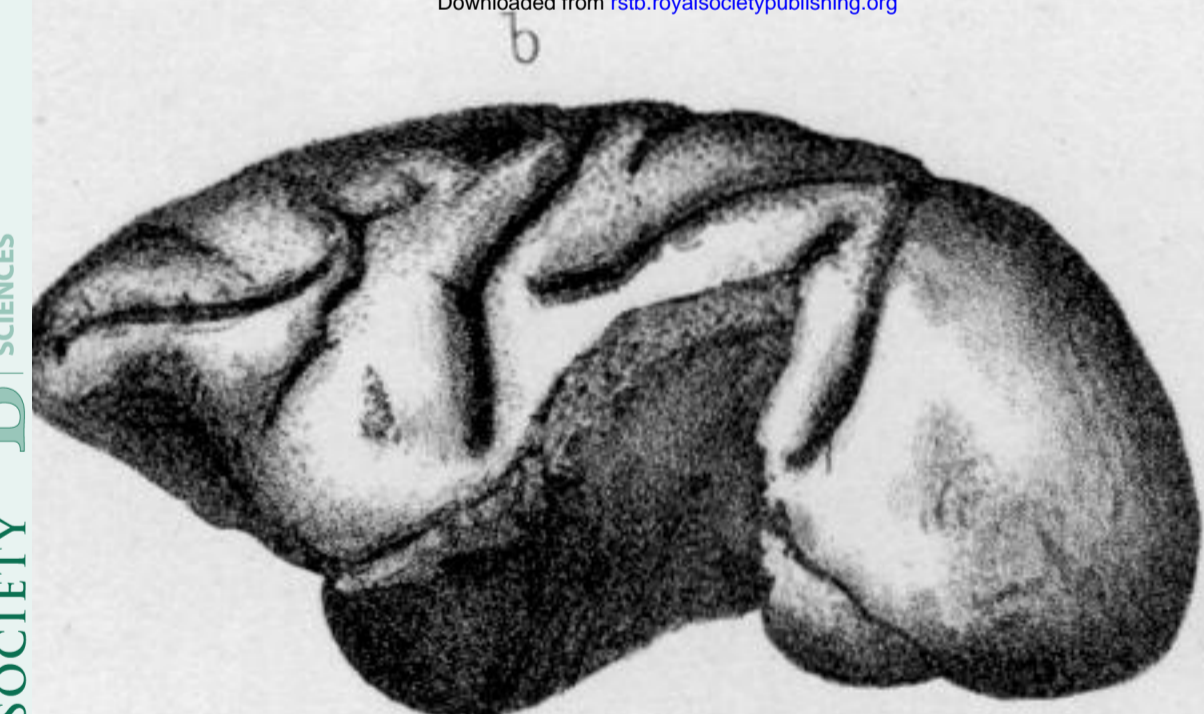
12. a.



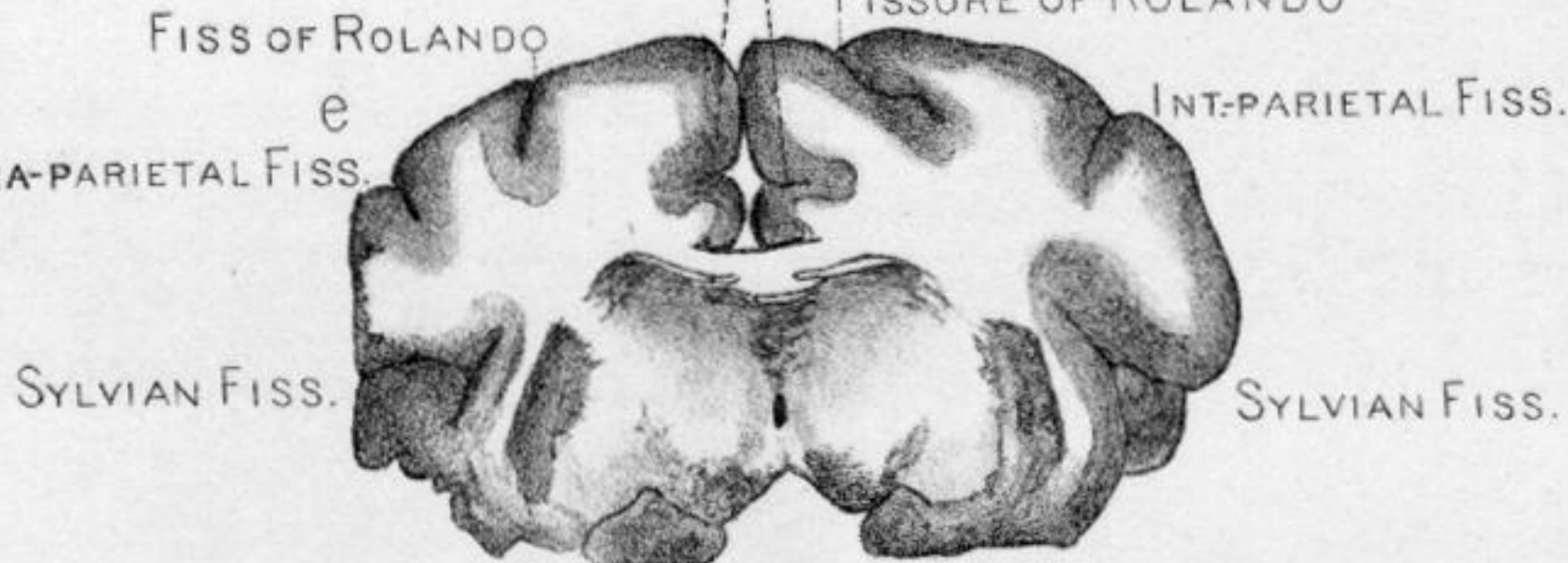
12. b.



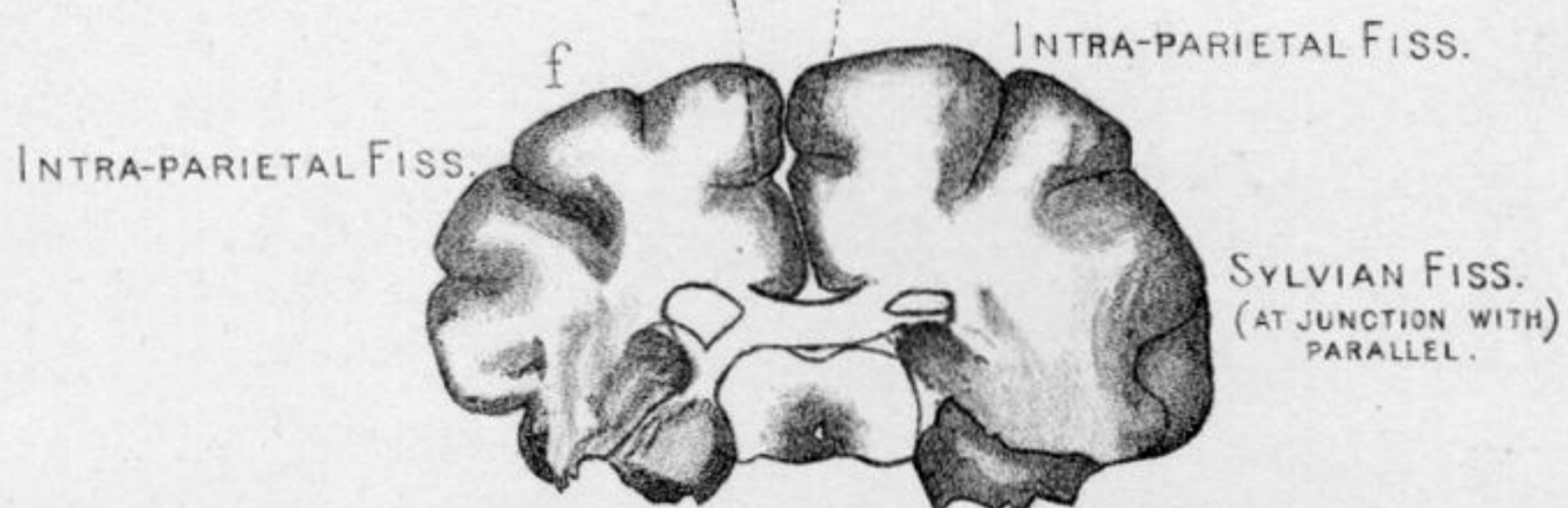
Downloaded from rstb.royalsocietypublishing.org

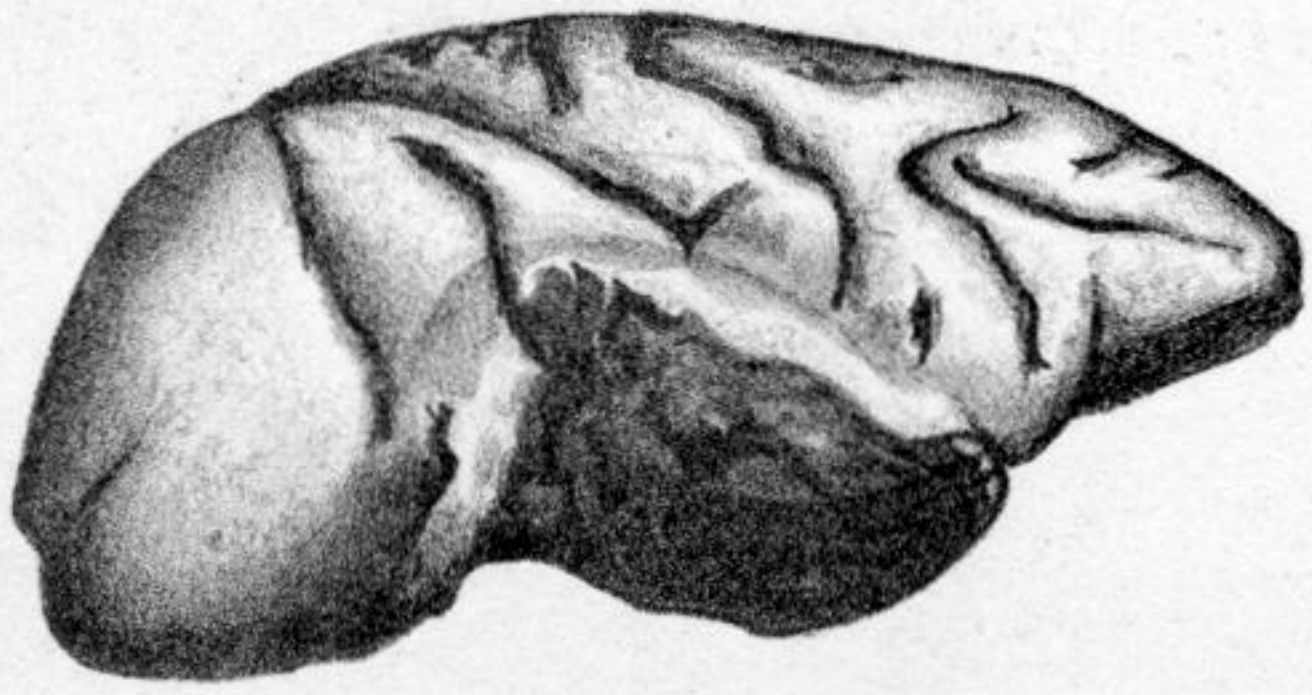

CALLOSO-MARGINAL FISS.
FISSURE OF ROLANDO
INT-PARIETAL FISS.

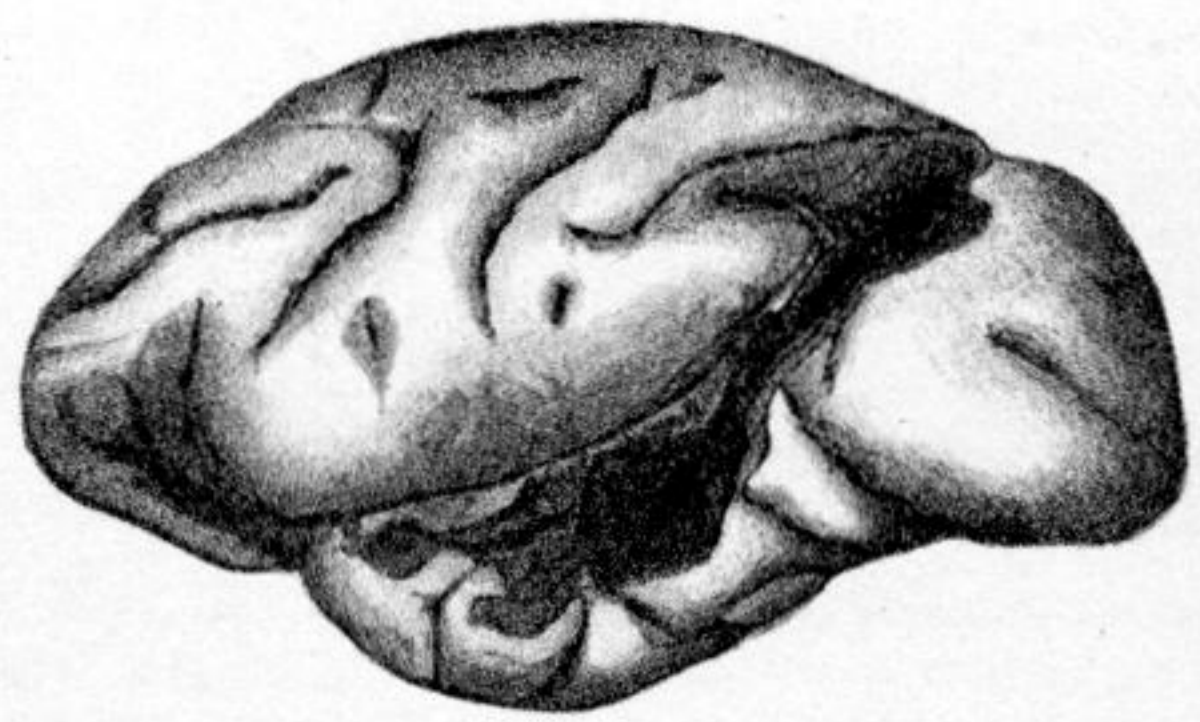


CALLOSO-MARGINAL FISS.
INTRA-PARIETAL FISS.

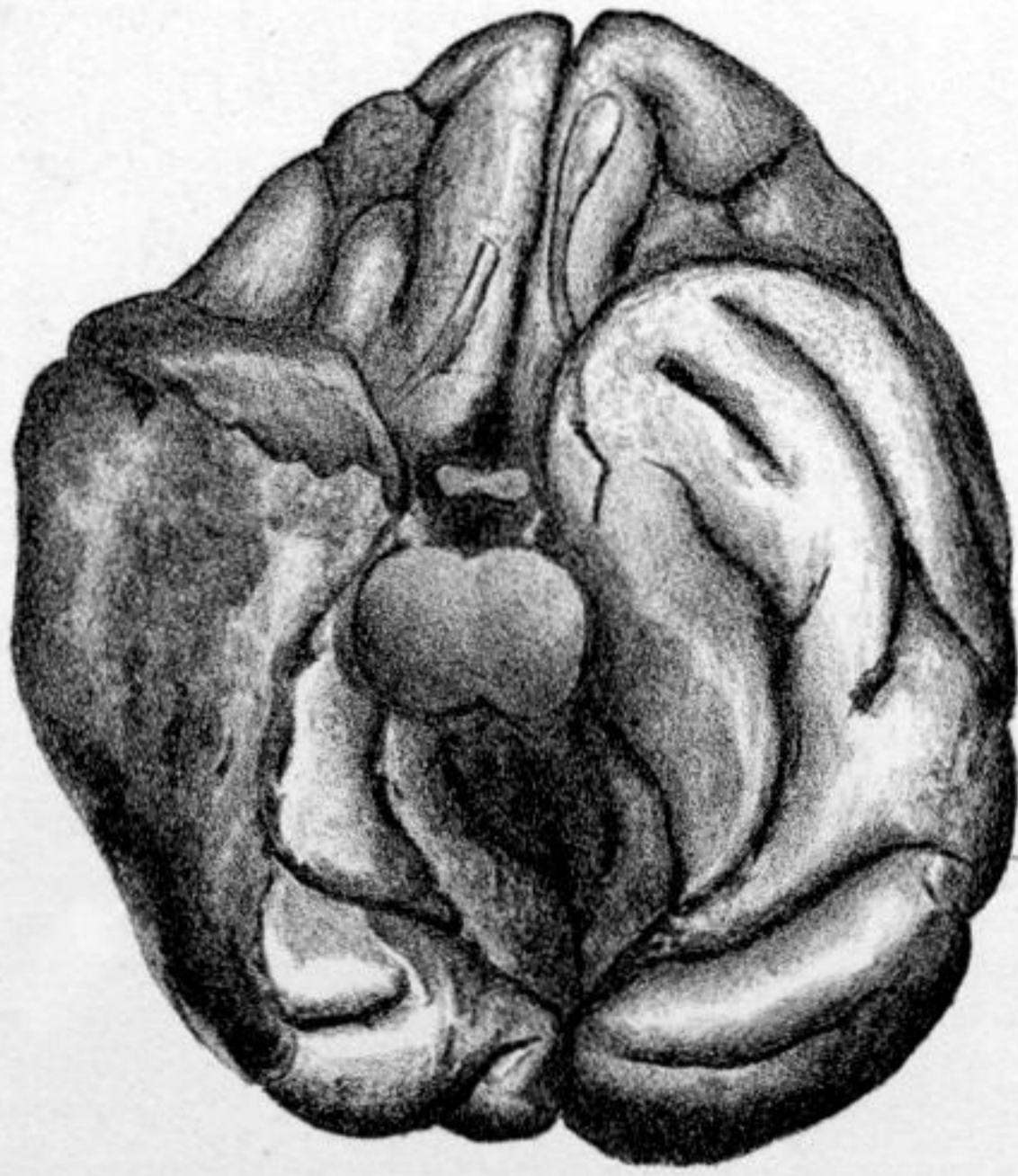




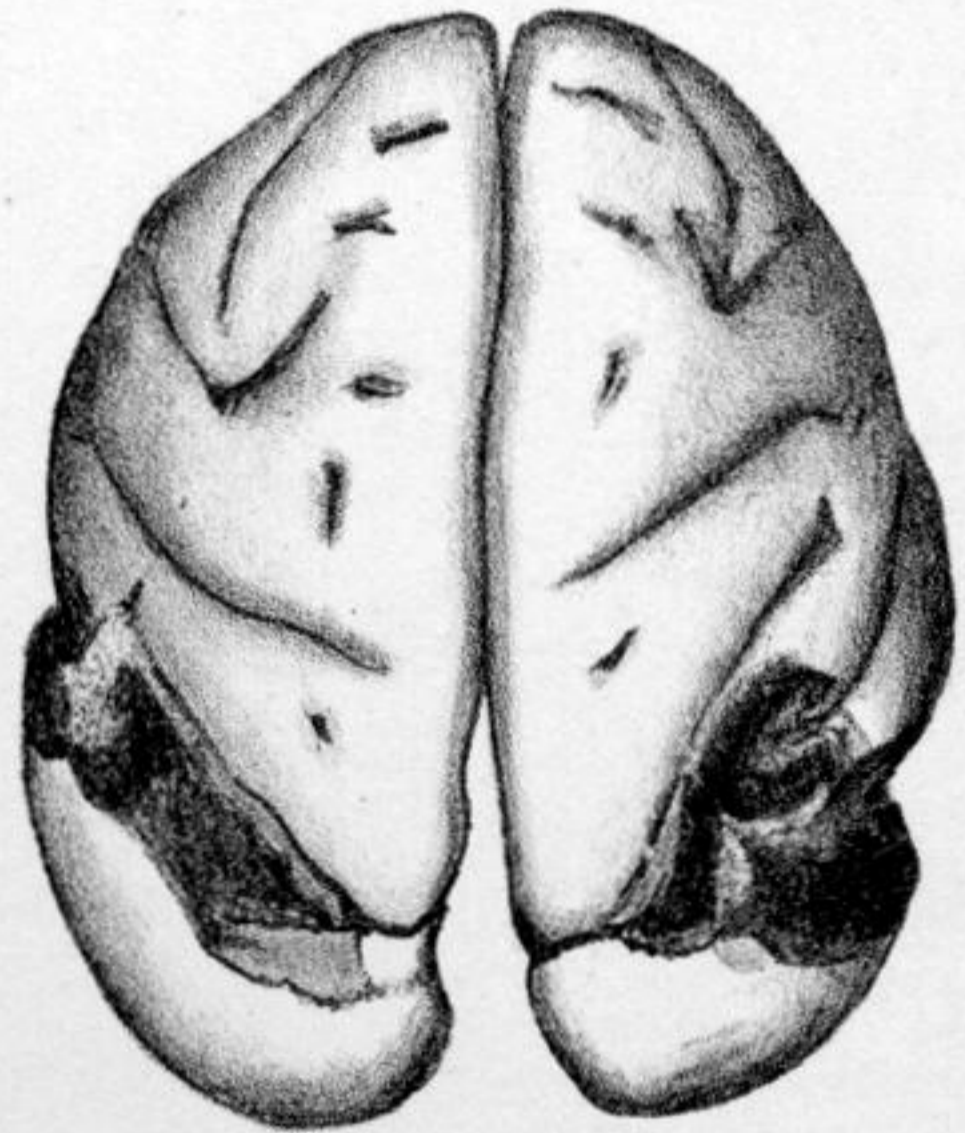
4. a.



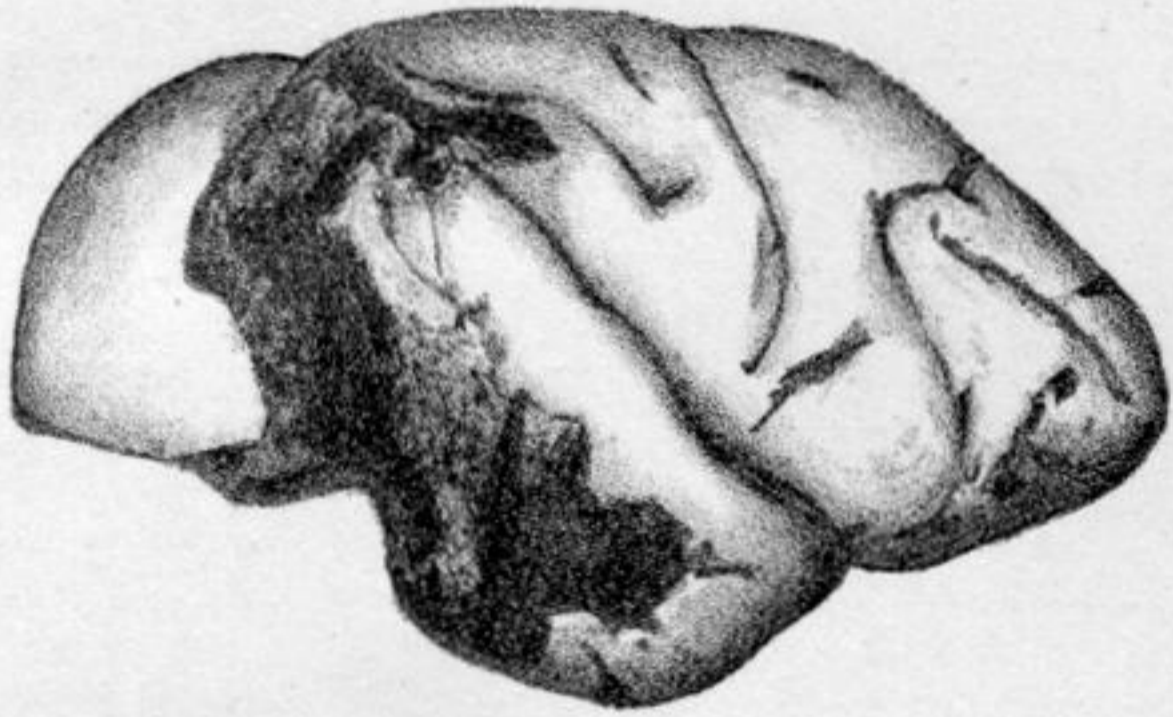5. a.



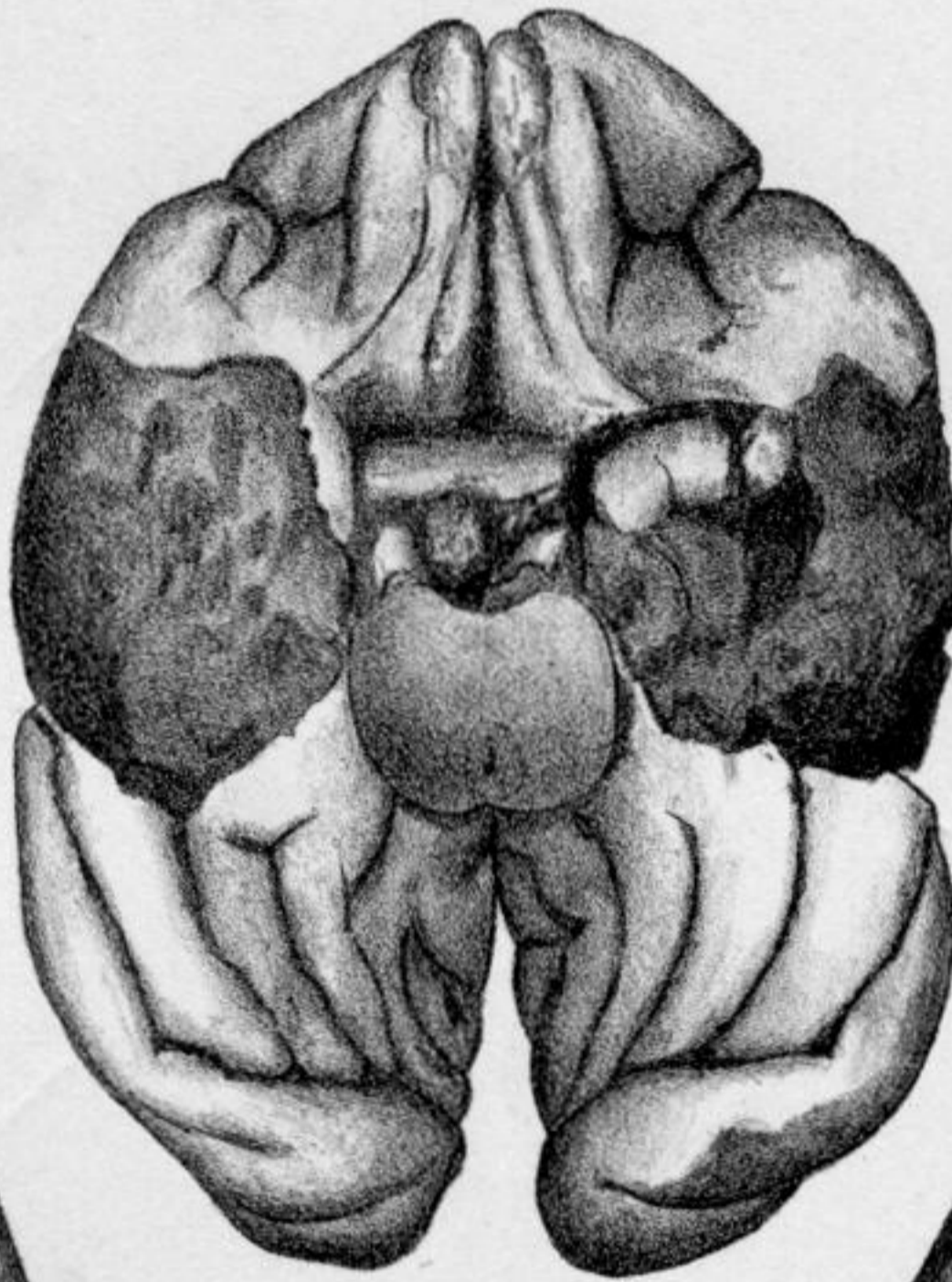
4. b.



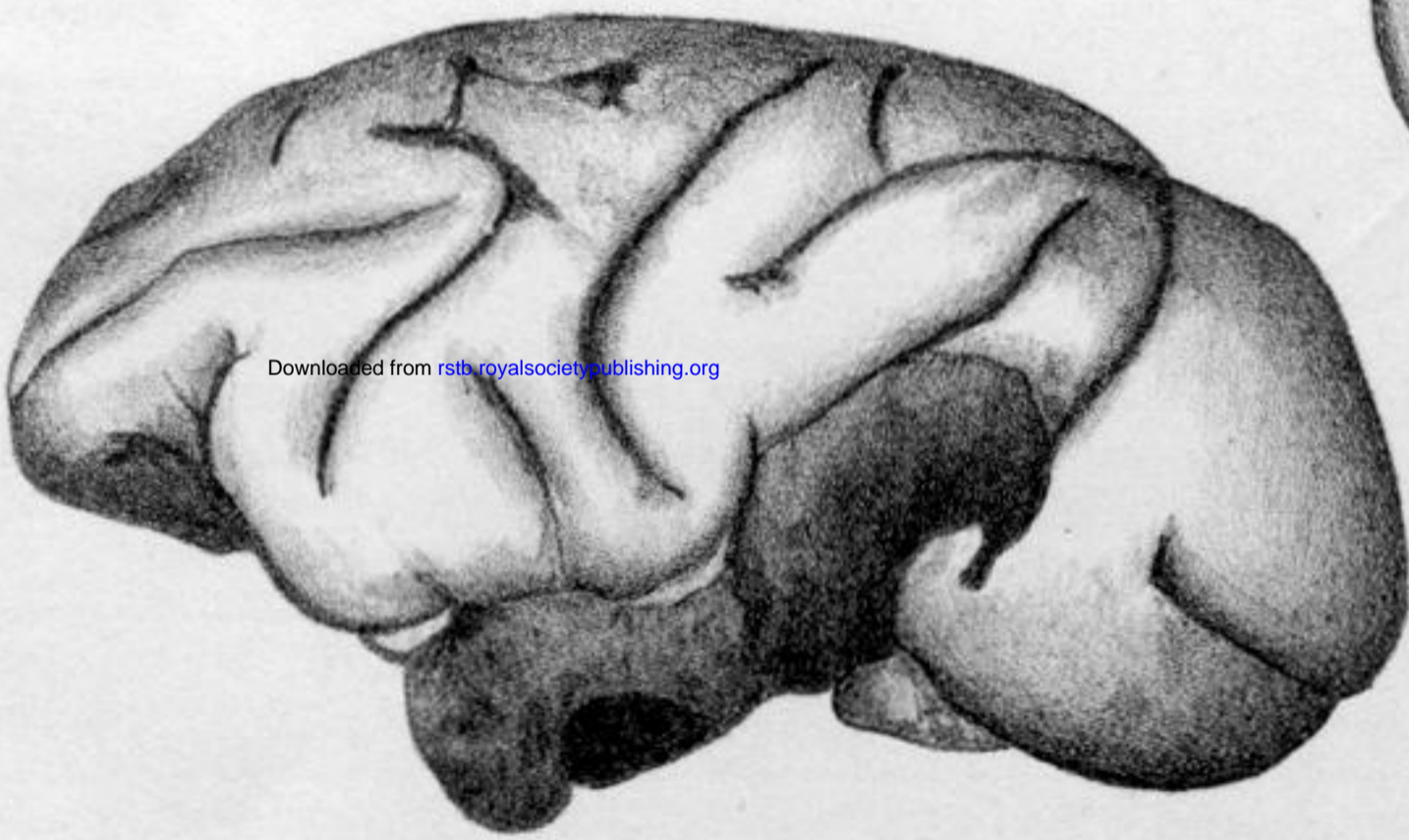
5. c.



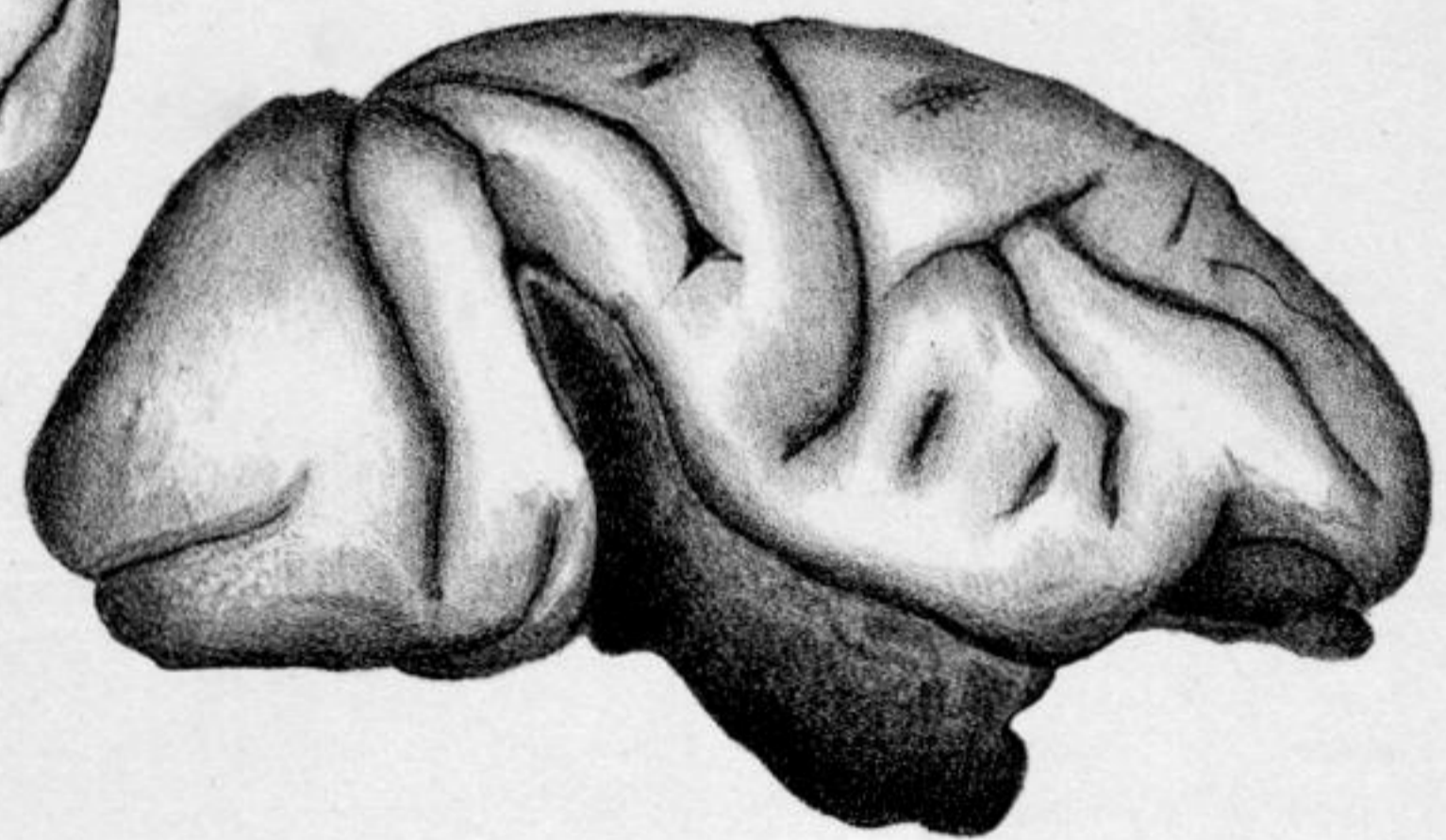5. b.



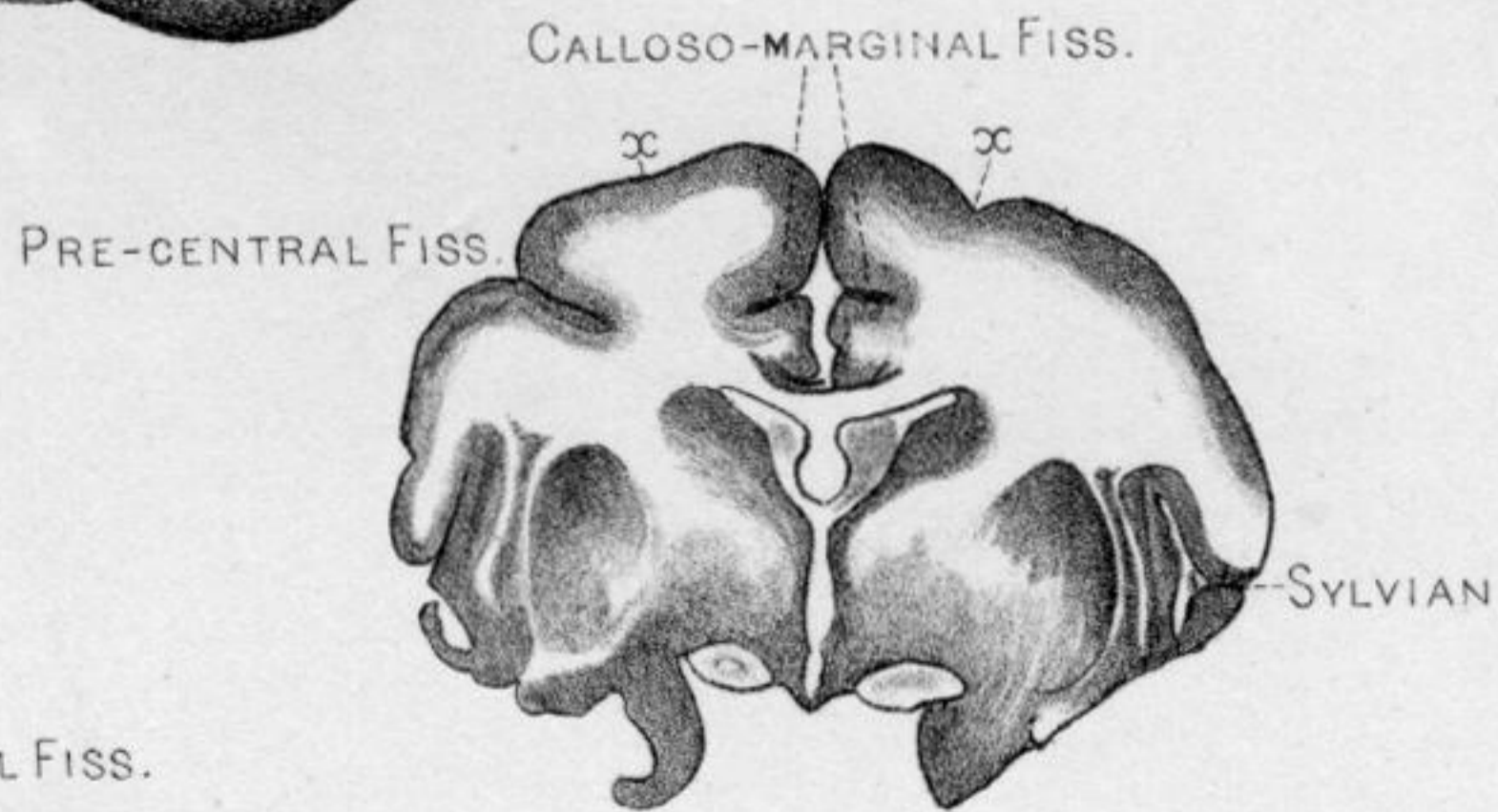
6. c.



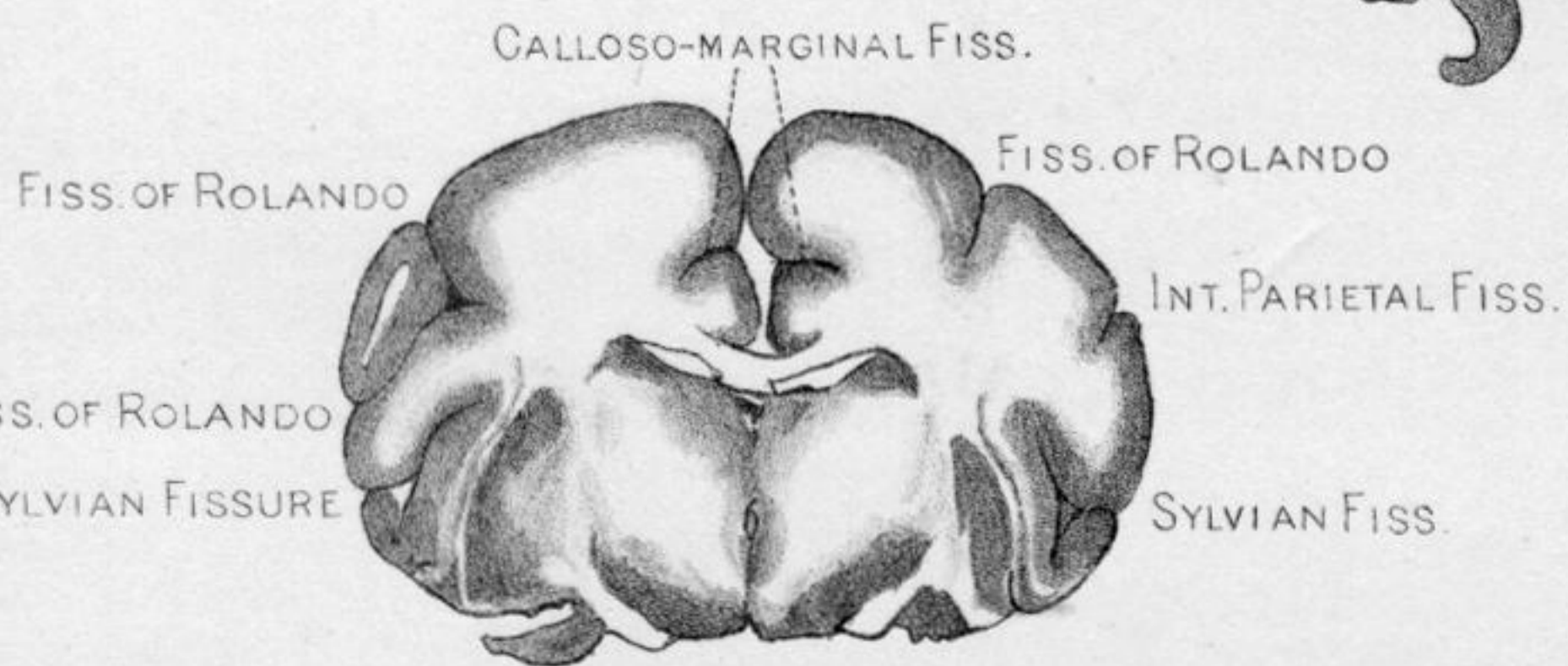
6. b.



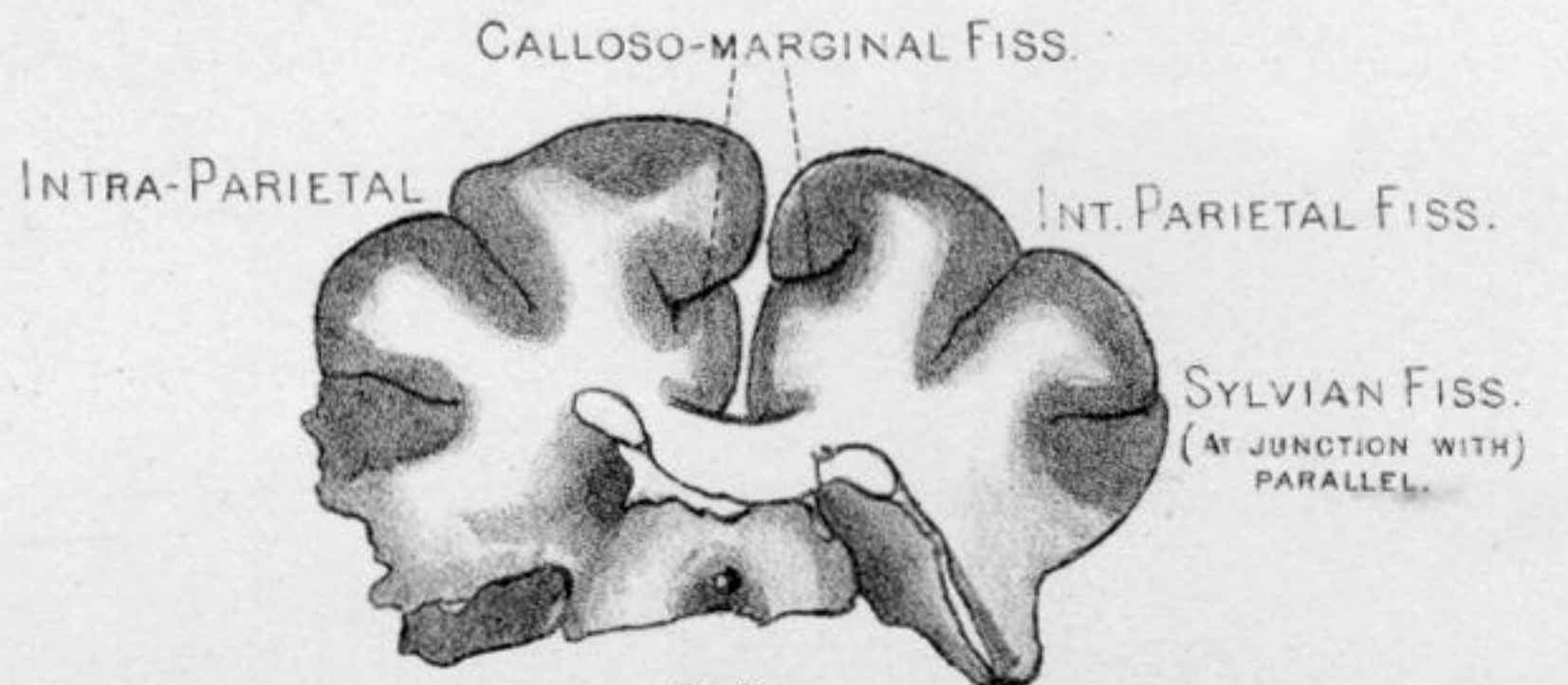
6. a.



6. d.

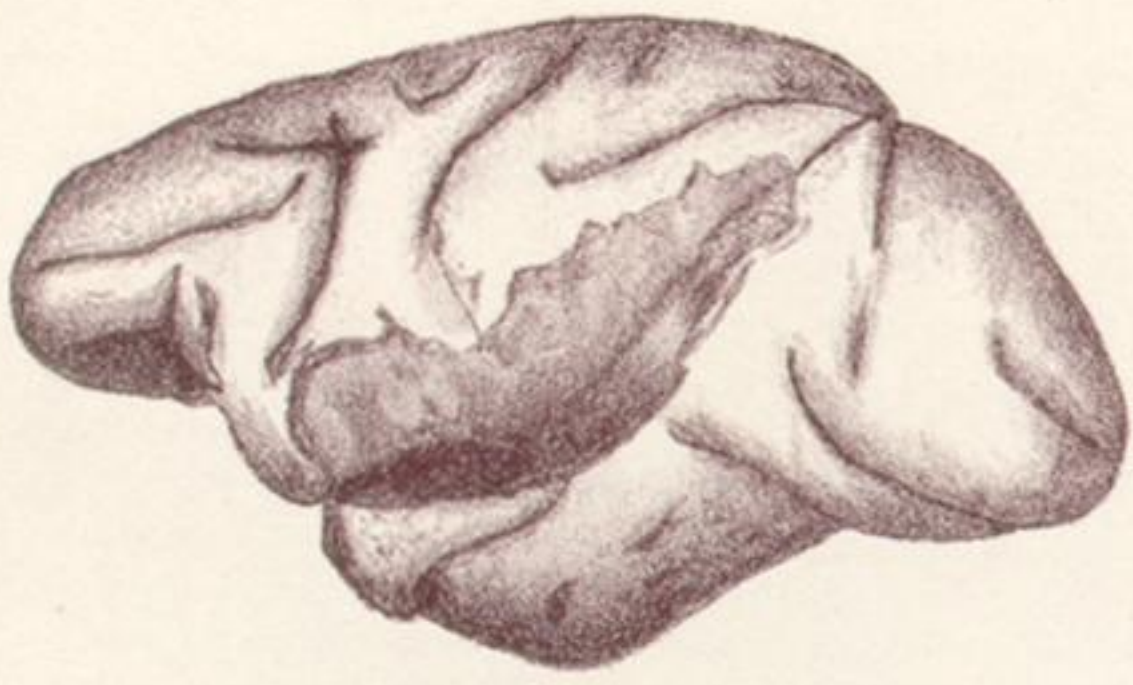

6. e.

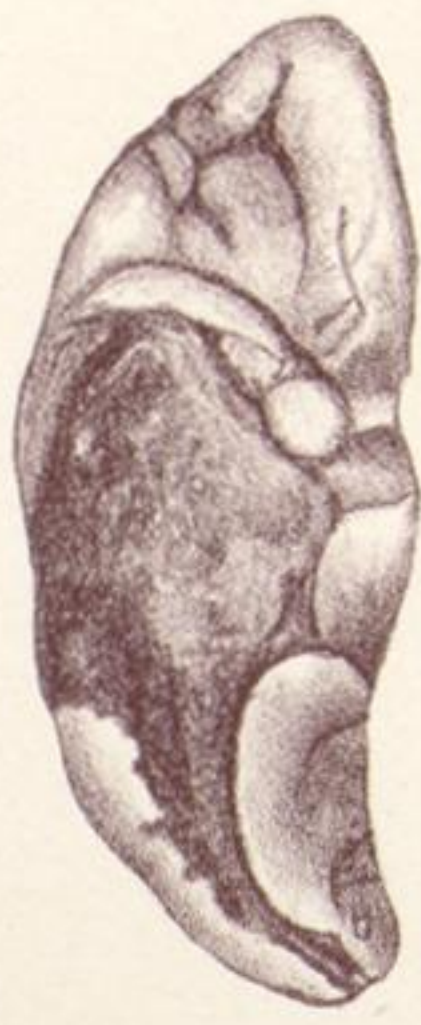

6. f.

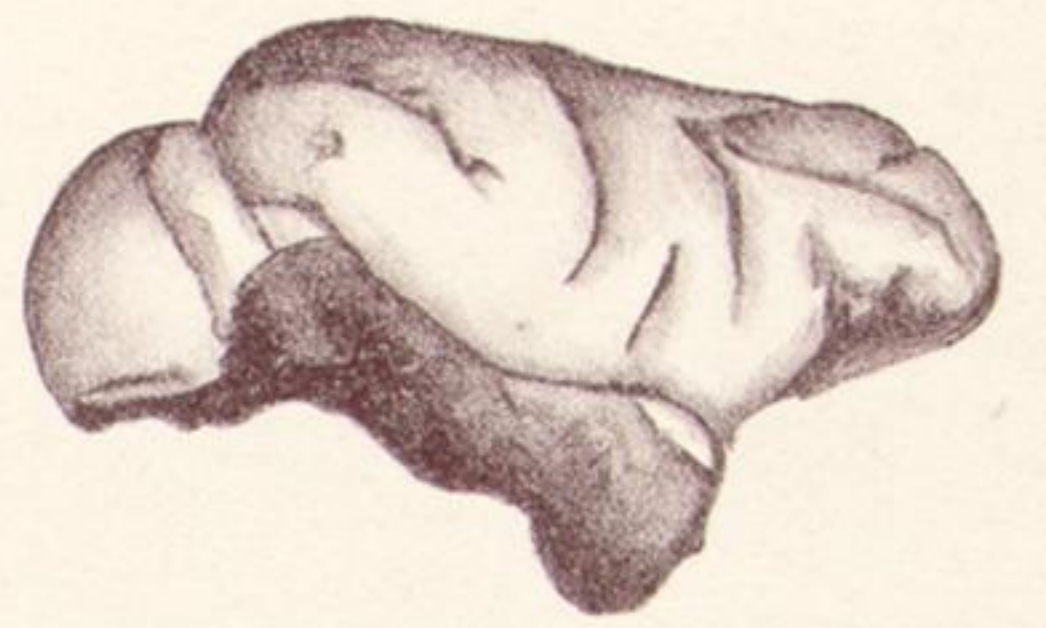Downloaded from rsta.royalsocietypublishing.org



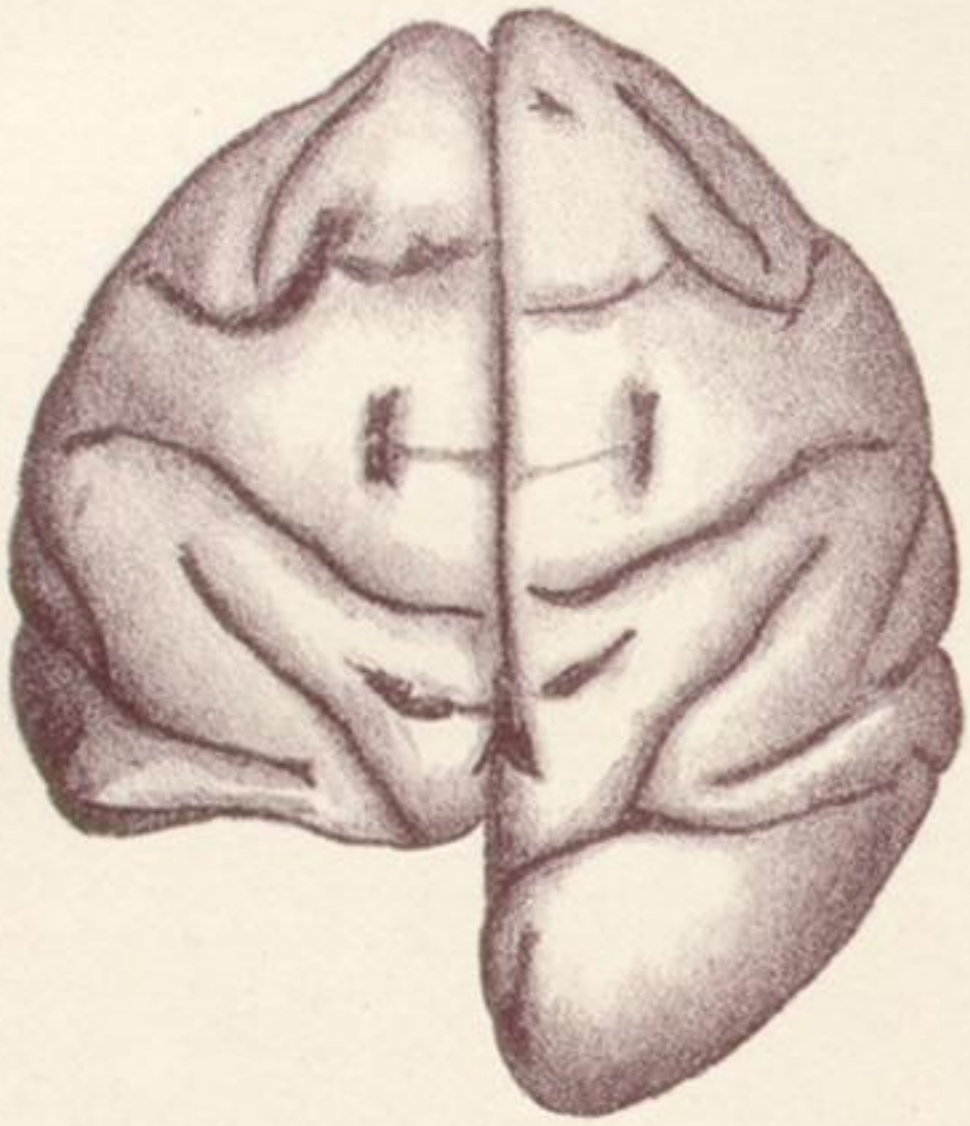
7. a.



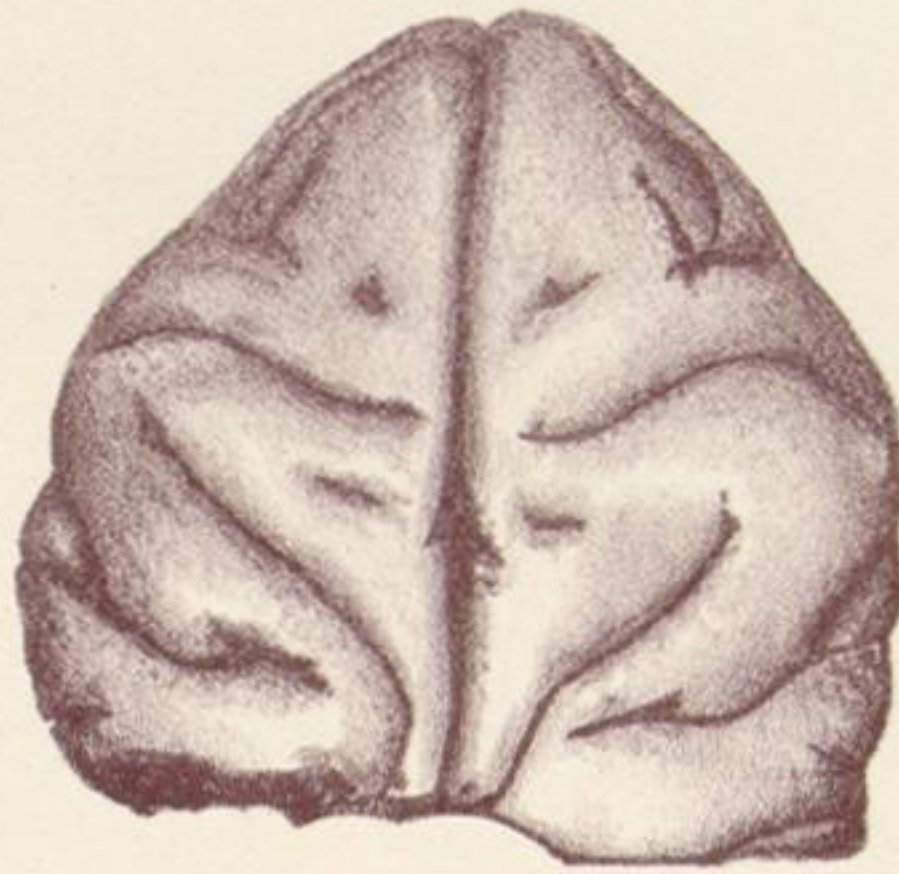
7. c.



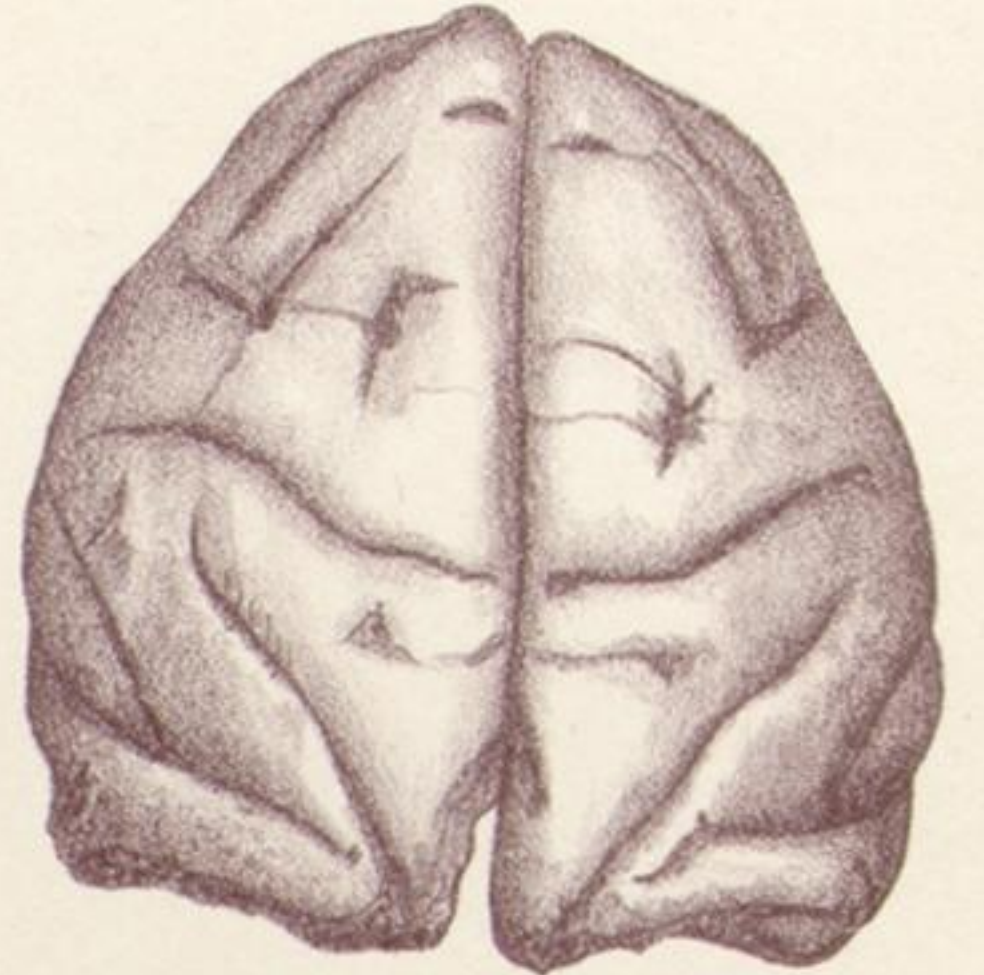
7. b.



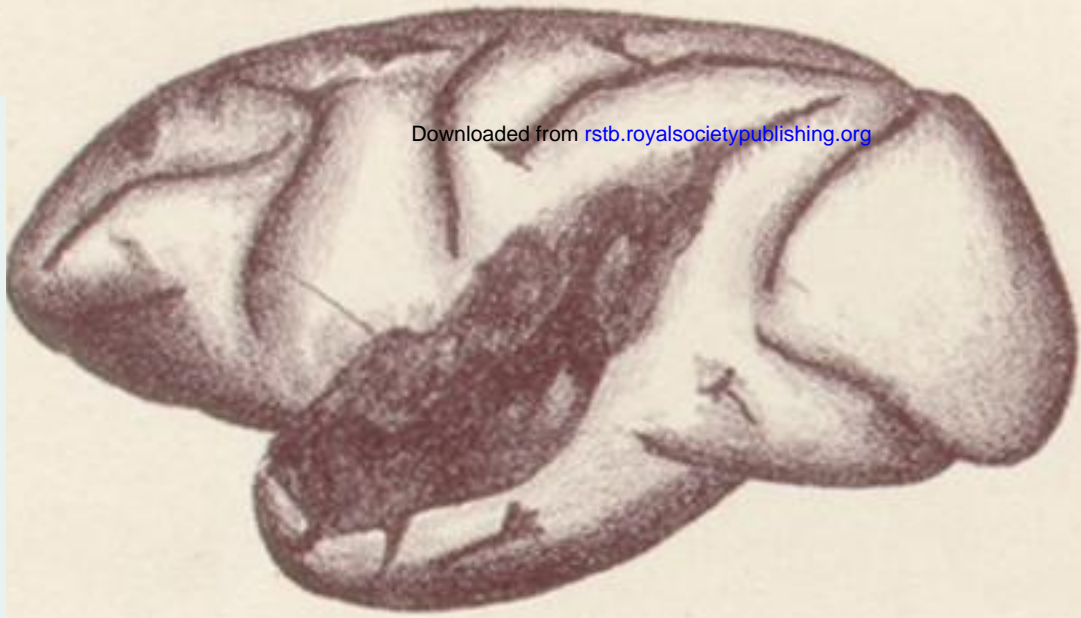8.



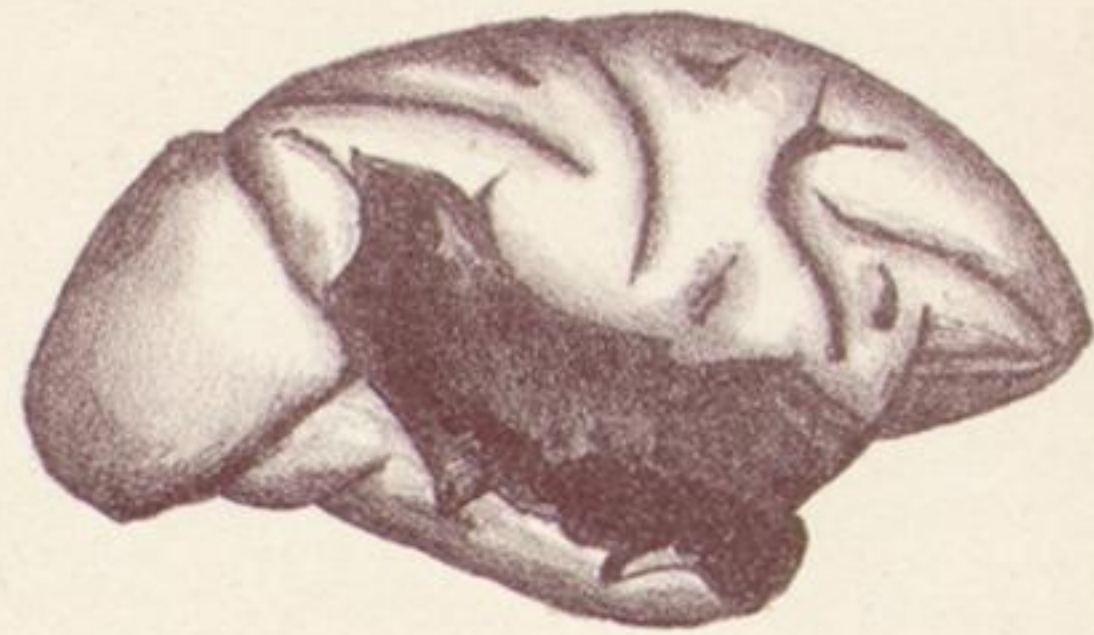9.



10. a.

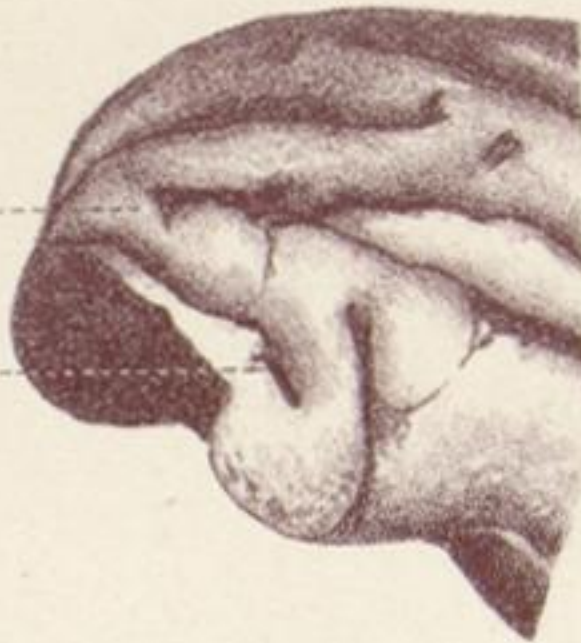

11. b.

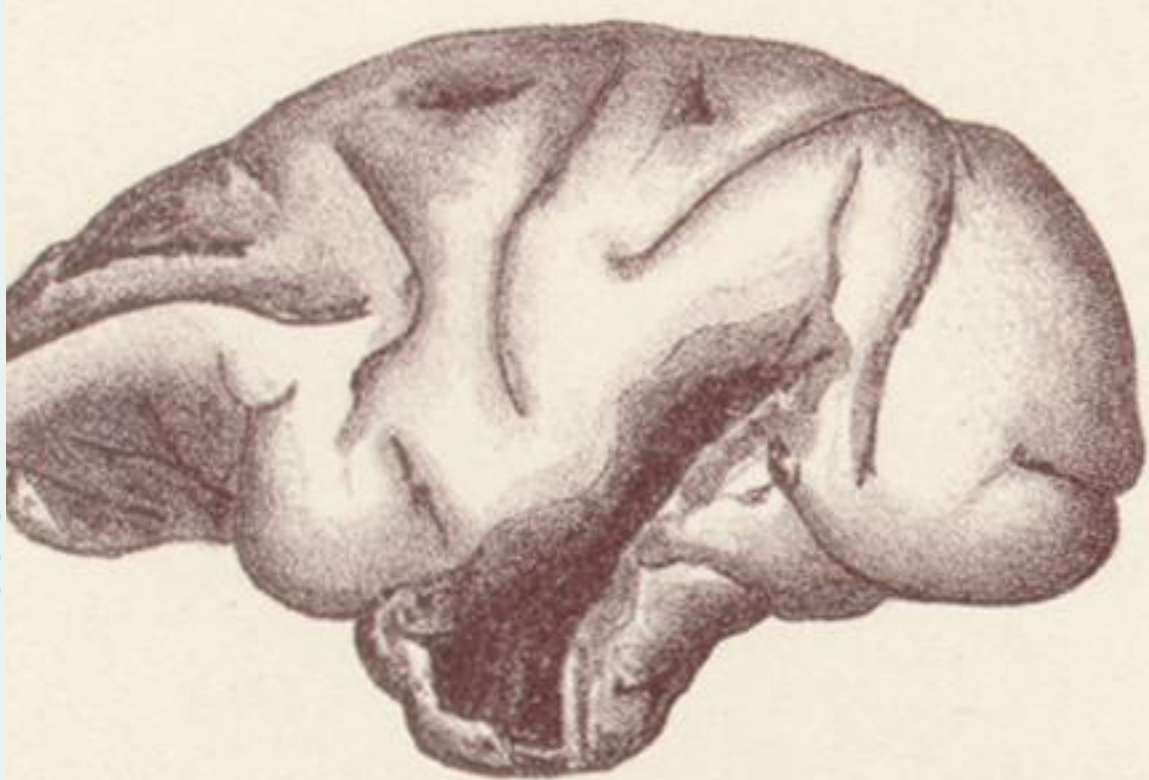

11. a.

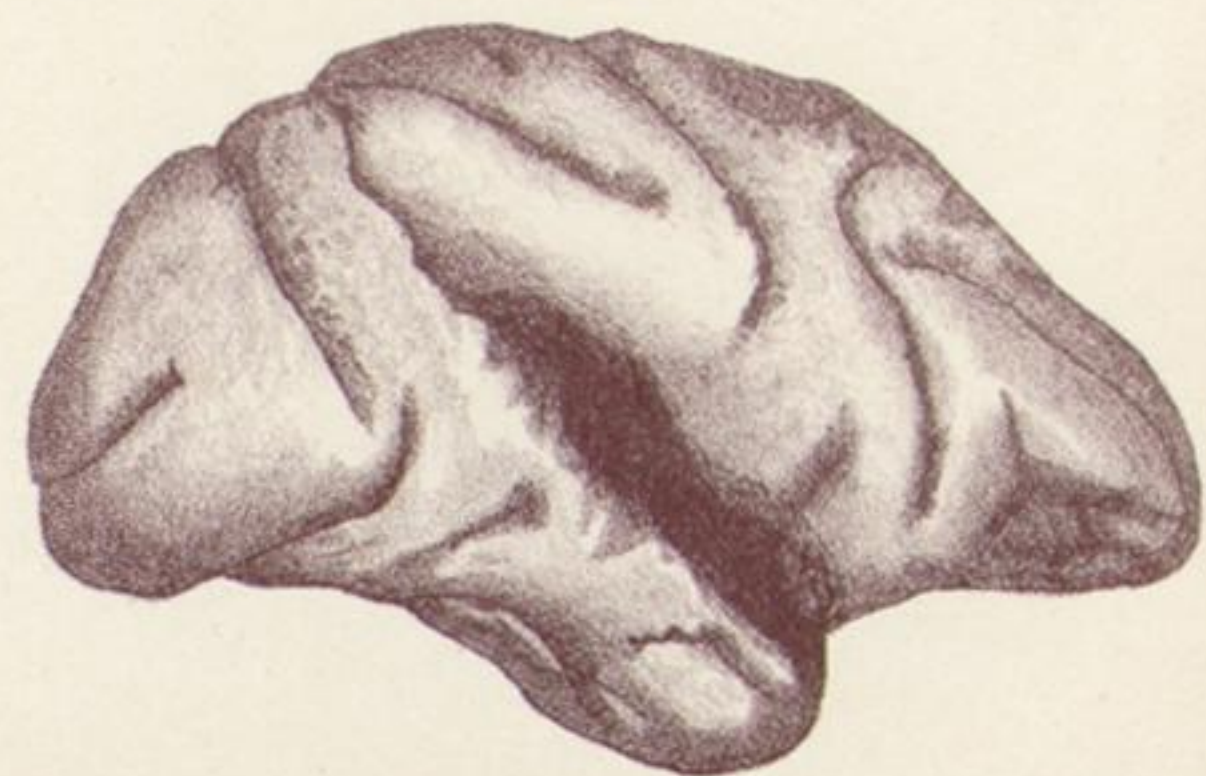ANGULARGYRUS.---
EXT. PAR. OCCIP. FISS.---



10. b.



12. a.



12. b.